

RESEARCH  
ARTICLE

 **Mehmet Ali Ozel<sup>1</sup>**  
 **Ramazan Buyukkaya<sup>2</sup>**

<sup>1</sup> Duzce University, Faculty of Medicine, Department of Radiology Duzce, Türkiye.

<sup>2</sup> Cappadocia Private Hospital, Department of Radiology, Türkiye

**Corresponding Author:**

Mehmet Ali Ozel  
 mail: mehmetali.ozel@duzce.edu.tr

Received: 06.11.2024

Acceptance: 15.05.2025

DOI: 10.18521/ktd.1580167

**Konuralp Medical Journal**

e-ISSN1309–3878

konuralptipdergi@duzce.edu.tr

konuralptipdergisi@gmail.com

www.konuralptipdergi.duzce.edu.tr

**Evaluation of Variations of the Chorda Tympani Nerve Originating from The Facial Nerve on High Resolution CT****ABSTRACT**

**Objective:** The aim of this study is to define the anatomical variations of the chorda tympani nerve originating from the facial nerve on high resolution CT (HRCT).

**Method:** A retrospective study of 100 patients who underwent temporal bone HRCT imaging in Duzce University, Department of Radiology. Individuals with normal bone structure at least on one side, were included in the study. Multiplanar reconstruction images were created then chorda tympani was imaged and measurements were performed.

**Results:** Thirty-seven bone were excluded. When the originating localizations of the chorda tympani from the facial nerve were examined, 19(11.7%) anterior, 85(52.1%) anterolateral, 55(33.7%) lateral and 4(2.5%) posterolateral origins. The distance from the origin of the chorda tympani to the stylomastoid foramen was measured as  $3.7 \pm 1.6$  mm. The originating angle of the chorda tympani from the facial nerve was measured as  $28.2 \pm 10.7^\circ$ . The widest distance between the chorda tympani and the mastoid segment of the facial nerve was measured as  $2.3 \pm 0.6$  mm. The furthest distance between the mastoid segment of the facial nerve and chorda tympani is inversely correlated with the distance between chorda tympani and stylomastoid foramen. The angle of originating chorda tympani from facial nerve is directly correlated with the distance between chorda tympani and stylomastoid foramen. The ratio of extratemporal branching of chorda tympani is %2.4.

**Conclusions:** The chorda tympani can be clearly seen on axial and reformat images on HRCT. Preoperative evaluation of the chorda tympani nerve might help to plan the surgical approach and thus prevent iatrogenic injury during middle ear surgery.

**Keywords:** Chorda Tympani, High Resolution CT, Facial Nerve, Posterior Tympanotomy, Facial Recess, Temporal Bone.

**Korda Timpani'nin Fasiyal Sinirden Çıkış Varyasyonlarının Yüksek Çözünürlüklü BT' de Değerlendirilmesi****ÖZET**

**Amaç:** Bu çalışmanın amacı, fasiyal sinirden köken alan korda timpani sinirinin anatomik varyasyonlarını yüksek çözünürlüklü BT'de (HRCT) tanımlamaktır.

**Yöntem:** Düzce Üniversitesi Radyoloji Anabilim Dalı'nda temporal kemik HRCT görüntülemesi yapılan 100 hastanın görüntüleri retrospektif olarak değerlendirildi. En azından bir tarafta normal kemik yapısına sahip bireyler çalışmaya dahil edildi. Multiplanar rekonstrüksiyon görüntüleri oluşturulduktan sonra korda timpani görüntülendi ve ölçümler yapıldı.

**Bulgular:** 37 kemik çalışma dışında tutuldu. Korda timpaninin çıkış lokalizasyonları incelendiğinde, 19 (%11.7) anterior, 85 (%52.1) anterolateral, 55 (%33.7) lateral ve 4 (%2.5) posterolateral orijinliydi. Korda timpaninin çıkışından stilomastoid foramene kadar olan mesafe  $3.7 \pm 1.6$  mm olarak ölçüldü. Korda timpaninin fasiyal sinirden çıkış açısı  $28.2 \pm 10.7^\circ$  olarak ölçüldü. Korda timpani ile fasiyal sinirin mastoid segmenti arasındaki en geniş mesafe  $2.3 \pm 0.6$  mm olarak ölçüldü. Fasiyal sinirin mastoid segmenti ile korda timpani arasındaki en uzak mesafe, korda timpani ile stilomastoid foramen arasındaki mesafe ile ters orantılıdır. Korda timpaninin fasiyal sinirden çıkış açısı, korda timpani ile stilomastoid foramen arasındaki mesafe ile doğrudan ilişkilidir. Korda timpaninin ekstraparotomal dallanma oranı %2.4' tür.

**Sonuç:** Korda timpani, HRCT'de aksiyel ve reformat görüntülerde açıkça görülebilir. Korda timpani sinirinin ameliyat öncesi değerlendirilmesi, cerrahi yaklaşımı planlamaya ve böylece orta kulak cerrahisi sırasında iatrogenik yaralanmayı önlemeye yardımcı olabilir.

**Anahtar Kelimeler:** Korda Timpani, Yüksek Çözünürlüklü BT, Fasiyal Sinir, Posterior Timpanotomi, Fasiyal Reses, Temporal Kemik.

## INTRODUCTION

Chorda tympani is the largest intratemporal branch of the facial nerve. It branches from the mastoid segment of the facial nerve, and this branching is extremely variable. Chorda tympani receives the sense of taste of the anterior 2/3 of the tongue and also provides parasympathetic innervation of the submandibular and sublingual glands. Iatrogenic damage to the chorda tympani is a well-known complication that develops after middle ear surgery (1). Damage causes taste disturbance and dry mouth (2). Because of its clinical importance and variation, chorda tympani should be evaluated on CT before surgery.

In this study, temporal bone high-resolution computed tomographies taken in our hospital were retrospectively scanned, and patients with normal middle-inner ear structure and ossicular chain were included in our study. The aim of this study is to help prevent injuries that may occur during middle ear surgeries by defining the distance of chorda tympani from the stylomastoid foramen, the furthest distance between the chorda tympani and the mastoid segment of the facial nerve, the branching angle of the chorda tympani from the facial nerve, the branching localization of the chorda tympani in the axial plane, whether the measurements are different in terms of gender and right-left.

## MATERIAL AND METHODS

**Ethics Approval:** This retrospective study was approved by our institutional ethics committee (Decision number: 2015/72) and carried out according to the requirements of the Declaration of Helsinki. Informed consent was waived because of the retrospective nature of the study.

**Patients:** For our study, high-resolution computed tomography (HRCT) examinations performed in the Department of Radiology, Faculty of Medicine, Düzce University were retrospectively reviewed. Individuals with normal middle and inner ear structure were included in the study group, those with congenital temporal bone anomaly, those who had previous temporal bone surgery, those with middle-inner ear and mastoid region pathologies (infection, trauma, tumor) and those with incompatible imaging parameters or artifacts on extraction were excluded. 100 individuals that meet all these criteria and can represent the normal population have been reached.

**Computed Tomography Protocol:** Temporal bone imaging examination was performed using a multidetector CT with the following parameters: 300 mAs, 120 kVp, a slice thickness of 0.5 mm, field-of-view 24 cm x 24 cm. The obtained 0.5 mm thick axial images were processed on the workstation and multiplanar reformatting (MPR) images were obtained. The evaluation was made by angling the axial, sagittal and coronal sections to best see them.

**CT Reviewing:** Images of the temporal bones were displayed using an DICOM Viewer. In the evaluation, first the styloid process was found in the axial plane and the stylomastoid foramen was visualized by following it. Then, the mastoid part of the facial nerve was followed and the branching of the chorda tympani was observed and the branching location was recorded. By following the anterolateral course of the chorda tympani in axial sections, the widest distance between the medial border of the chorda tympani and the lateral border of the facial nerve was measured. Then, reformat images were created, the mastoid part of the facial nerve was rotated around its own axis so that it was vertical, a plan in which the branching angle of the chorda tympani was most clearly visible was obtained, and the branching angle was measured. Finally, the exact point where the borders of the stylomastoid foramen formed was determined and the distance of the branching point of the chorda tympani to the stylomastoid foramen was recorded.

**Statistical Analysis:** Statistical analyses were performed with SPSS 22.0 (IBM Inc., Chicago, Illinois, USA). To compare the groups, Independent Samples t test was used for two groups and One-Way ANOVA was used for three or more groups. The difference between right and left measurements was examined with Paired Samples t test. Relationships between categorical variables were examined with the Fisher-Freeman-Halton test. Correlations between continuous variables were examined with Pearson correlation analysis. Statistical differences were considered significant with  $P < 0.05$ .

## RESULTS

One hundred patients who underwent CT of the temporal bone were included in the study. A total of 163 temporal bones in 100 patients were evaluated. The median age was 36 years and 57% ( $n = 57$ ) of patients were women. There was no significant difference between the genders in terms of age ( $P = 0.57$ ). The localization of branching of the chorda tympani from the facial nerve was observed anterior in 19 (11.7%), anterolateral in 85 (52.1%), lateral in 55 (33.7%), and posterolateral in 4 (2.5%) (Table 1).

**Table 1.** Distribution of branching localization of chorda tympani from facial nerve

Localization	Number	Percentage (%)
Anterior	19	11.7 %
Anterolateral	85	52.1 %
Lateral	55	33.7 %
Posterolateral	4	2.5 %
<b>Total</b>	<b>163</b>	<b>100 %</b>

There was no significant difference between the two genders in terms of the localization of the branching of the chorda tympani from the facial nerve ( $p=0.7$ ). The distance of the branching point of the chorda tympani to the stylomastoid foramen was  $3.7\pm1.6$  mm, the branching angle of the chorda tympani from the facial nerve was  $28.2^\circ\pm10.7$ , and the widest distance between the chorda tympani and the mastoid segment of the facial nerve was  $2.3\pm0.6$  mm. The distance of the branching point of the chorda tympani from the facial nerve to the stylomastoid foramen was  $4.18\pm1.66$  mm in males and was statistically significantly higher than in females ( $p=0.002$ ) (Table 2). There was no significant difference between the genders in other

measurements. There is a weakly significant inverse correlation between the largest distance between chorda tympani and facial nerve and the distance of the branching point of chorda tympani from the facial nerve to the stylomastoid foramen ( $r=-0.42$ ,  $p<0.001$ ). There is a weakly significant same-way correlation between the branching angle of the chorda tympani from the facial nerve and the distance from the branching point of the chorda tympani to the stylomastoid foramen ( $r=0.38$ ,  $p=0.001$ ). The distance of the anterior branching nerves to the stylomastoid foramen was significantly higher than the other localizations ( $p=0.009$ ).

**Table 2.** Variables in measurements depending on gender

Variable	Gender	Number	Mean	Standart Deviation	p
Distance (mm)	Female	91	3.38 mm	1.63	<b>0.002</b>
	Male	72	4.18 mm	1.66	
Aperture (mm)	Female	94	2.34 mm	0.62	0.623
	Male	73	2.29 mm	0.61	
Angle (°)	Female	91	29.14°	10.50	0.237
	Male	72	27.13°	11.01	

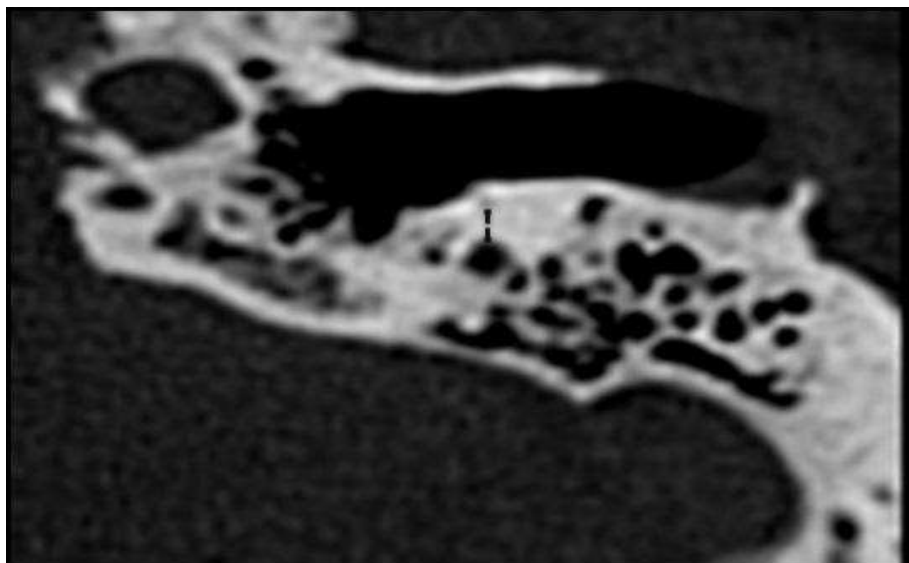
**Distance:** Distance of the branching point of the chorda tympani to the stylomastoid foramen. **Aperture:** Widest distance between the chorda tympani and the mastoid segment of the facial nerve. **Angle:** Branching angle of the chorda tympani from the facial nerve

## DISCUSSION

Nowadays, helical CT is the gold standard in temporal bone imaging because it has a high ability to show bone structures (3). Evaluation of the middle and inner ear on CT is very important for detecting pathologies, and evaluation with CT is becoming increasingly important before very sensitive ear surgeries (4).

Although it has been reported that chorda tympani can be detected on high-resolution CT, there are few studies on its sensitivity and accuracy. In a study conducted by Parlier-Cuau et al., it was stated that the detection of chorda tympani in high-

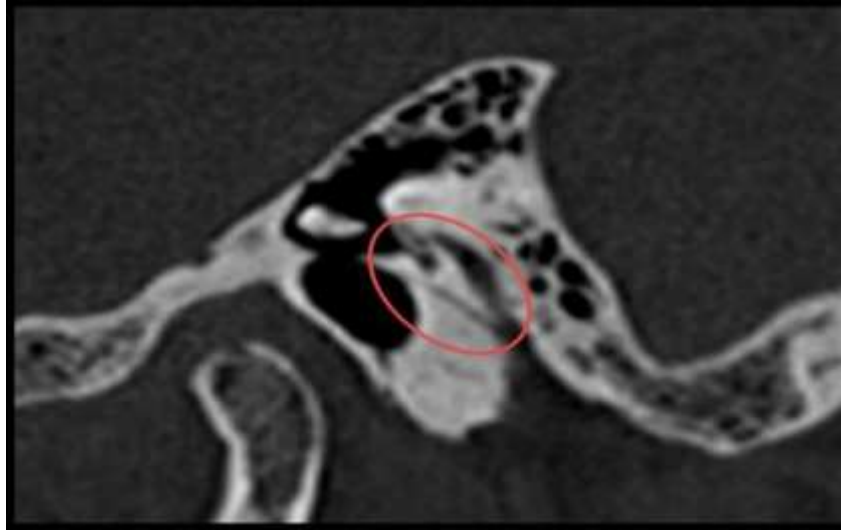
resolution CT was best seen in axial sections, and the detection rate was reported to be as low as 71% (5). We were able to detect chorda tympani in all the bones we examined. The reason why the rate was so low in the study conducted by Parlier-Cuau et al. may be that the sections were taken wide because the protocol used in that study was 300mA, 130 kVp, 1.2 mm section thickness. Although mA and kVp values are similar to our study, the section thickness is quite high. For this reason, taking the section thickness of 0.5 mm, as we did, may be sufficient to detect chorda tympani.



**Figure 1.** Measurement of the distance between the chorda tympani and the facial nerve.

Facial recess is defined as the widest distance between the chorda tympani and the facial nerve (Figure 2). This distance varies for each patient. Therefore, this area should be evaluated before middle ear surgeries. In our study, facial reses was measured  $2.3 \pm 0.6$  mm. In the literature, this distance was measured  $1.4 \pm 0.7$  mm by Dalveer Singh et al. (4),  $2.9 \pm 0.7$  mm by Lauren J. McManus et al. (1), and  $3.6 \pm 0.2$  mm by Eun-Ju Jeon et al. (6). There is no statistically significant difference

between the two temporal bones in terms of facial recess. Dalveer Singh et al. also reported that there was no statistically significant difference between the two sides (4). Therefore, if the chorda tympani can not be clearly displayed on one side for various reasons, the opposite side can be taken as a reference (4). However, it should be kept in mind that in cases that cause mastoid sclerosis, such as chronic otitis media, the facial recess may be narrower than the normal side (7).

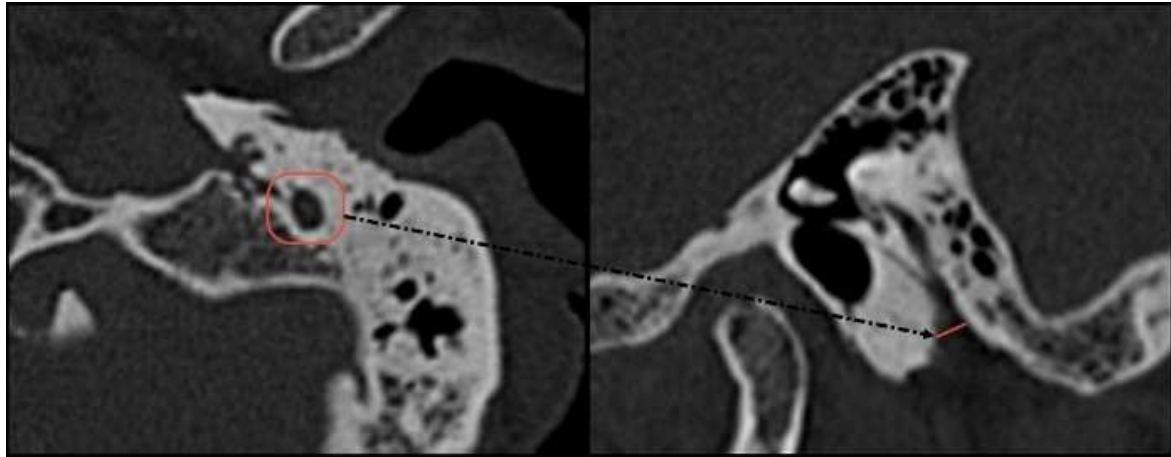


**Figure 2.** Facial recess

If the distance between the chorda tympani and the vertical part of the facial nerve is 1 mm or less, it is considered a narrow facial recess (8). A narrow facial recess makes cochleostomy difficult and may cause damage to the facial nerve (6). In a study of 1402 patients, Line Wang et al. reported that 39 patients had narrow facial recess, of which 22 patients had a facial recess width of 0.7-0.8 mm, and 17 patients reported that it was 0.8-1.0 mm (8). We measured the facial recess as 0.9-1.0 mm in 4 of the 100 patients we included in our study. Detecting the narrow facial recess before the operation and deciding which surgical technique will be applied will help to prevent intraoperative facial nerve or chorda tympani damage.

In our study, a weakly significant inverse correlation was found between the distance between the chorda tympani and the facial nerve mastoid segment and the distance from the branching point of the chorda tympani to the stylomastoid foramen. In other words, the closer the chorda tympani branching point is to the stylomastoid foramen, the greater the width of the facial recess. Similarly, Dalveer Singh et al. concluded in their study that the lower the chorda tympani branches in the temporal bone, the wider the distance between the chorda tympani and the mastoid segment of the facial nerve (4).

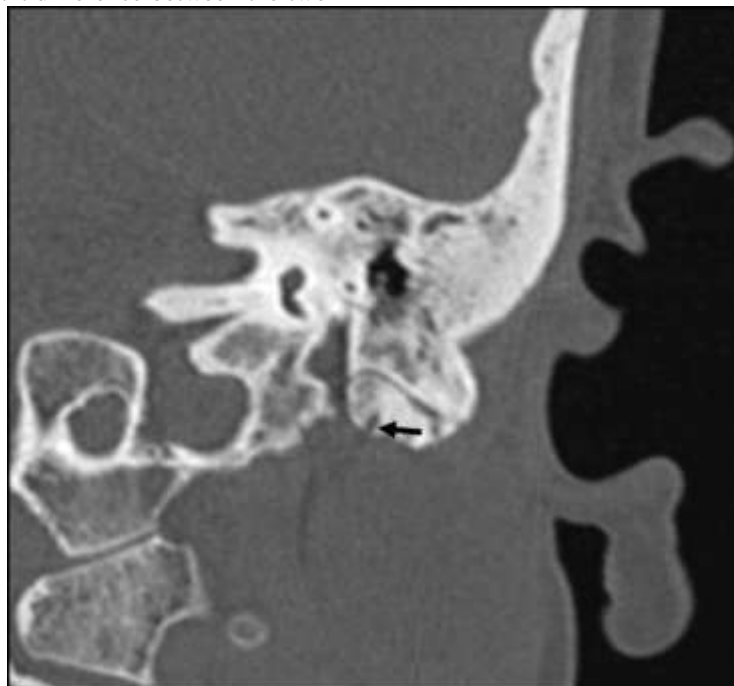
While the labyrinthine and tympanic segments of the facial nerve do not lengthen with age, the mastoid segment does. The mastoid part of the temporal bone also grows with age. Since the growth rate of the mastoid bone is higher than the growth rate of the mastoid segment of the facial nerve, the branching of the chorda tympani, which is extratemporal at birth, is located intratemporal in adulthood. Since the development of the mastoid part varies among individuals, the distance of the branching point of the chorda tympani to the stylomastoid foramen is also variable (9). We found the distance of the branching point of the chorda tympani to the stylomastoid foramen as  $3.7 \pm 1.6$  mm. This distance was found as 4.02 mm (9), 3.2 mm (1), 2.67 mm (10), 3.17 mm (11), 5.3 mm (12), 4.8 mm (13) in previous studies. There may be two reasons why there are such different values; Firstly, it may be due to the difference in measurement technique. Because in most previous studies, measurements were made without the definition of stylomastoid foramen. We considered the non-defective point where the facial nerve enters the temporal bone from the neighborhood of the styloid process, and whose borders are completely surrounded by bone structure, as the stylomastoid foramen (Figure 3).



**Figure 3.** Detection of stylomastoid foramen

Lauren J. McManus et al. also made a similar definition (1). Secondly, it may be that the development of the mastoid part differs according to races (11). Because in studies, the extratemporal branching rate of chorda tympani was found to be 15% in New Zealand (1), 2-5% in Europe (12,14), and 53% in China (11). In our study, this rate was found to be 2.45% (Figure 4). This may show us that the development of the mastoid bone may be different depending on race. Lauren J. McManus et al. in their study, they found that the branch point of the chorda tympani was closer to the stylomastoid foramen on the right (1). In our measurements, there was no significant difference between the two

sides. Studies have shown that the distance between the stylomastoid foramen and the branching point of the chorda tympani differs racially (11). However, to the best of our knowledge, our publication is the first to show in the literature that the distance between the chorda tympani branch point and the stylomastoid foramen differs depending on gender. In our study, this distance was found to be  $3.38 \pm 1.63$  mm in females and  $4.18 \pm 1.66$  mm in males. The distance of the branching point of the chorda tympani to the stylomastoid foramen is significantly greater in males than in females. In other words, the chorda tympani branches higher in males.

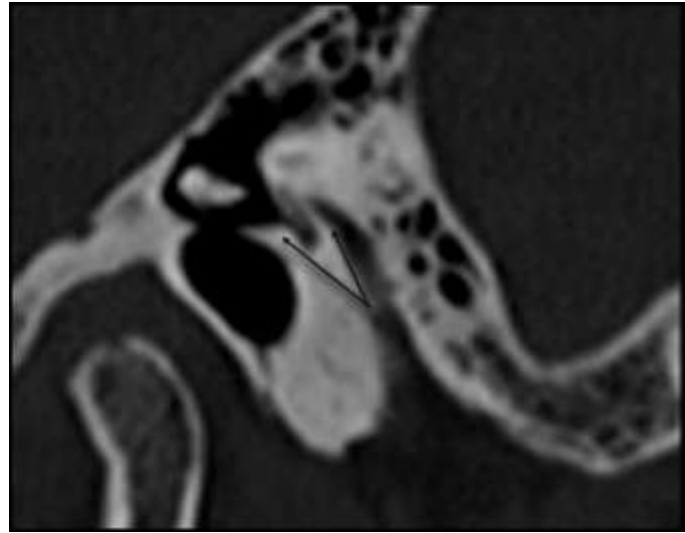


**Figure 4.** Extratemporal branching of the chorda tympani

We found the angle between the branching point of the chorda tympani and the facial nerve as  $28.2^\circ \pm 10.7$ . In a cadaver study conducted in Turkey in 2010, it was found to be  $23.5^\circ \pm 6.8$  (15). In another study, it was measured as  $18.4^\circ \pm 1.05$  (6). Eun-Ju Jeon et al. they stated that the reason for

the difference in measurements may be because they used different anatomical points in the measurements (6). In angle measurements, we measured the angle between the lateral border of the facial nerve and the medial border of the chorda tympani (Figure 5).

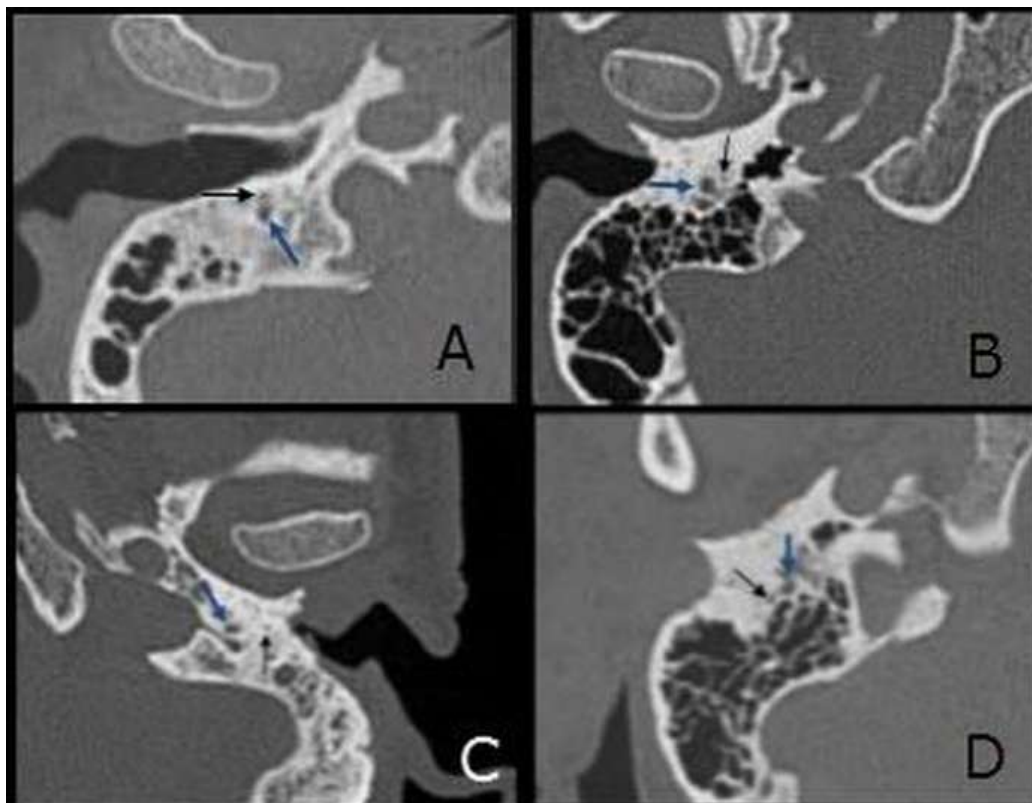




**Figure 5.** Measurement of the branching angle of the chorda tympani.

Another point that caught our attention in our measurements was that there was the same directional correlation between the branching angle of the chorda tympani and the distance from the branching point to the stylomastoid foramen. In other words, the closer the chorda tympani branches to the stylomastoid foramen, the narrower the angle. Line Wang et al. suggested in their study that the facial recess may narrow as this angle decreases (8), but in our study, there was no statistically significant linear relationship between the distance between the facial nerve and the chorda tympani and the branching angle of the chorda tympani.

It has been observed that the chorda tympani branches from different locations in the axial plane (Figure 6). Despite this difference, chorda tympani shows an anterolateral course in all bones. In a previous study, 54 temporal bones were examined and it was observed that the chorda tympani had an anterolateral origin in all of them (4). In another study, it was classified into two groups as lateral and posterolateral exit (16). When we examined by gender, we found that there was no significant difference in chorda tympani branching locations depending on gender.



**Figure 6.** Branching locations of the chorda tympani in axial sections. A) Anterior B) Anterolateral C) Lateral D) Posterolateral. Black arrow indicates chorda tympani, blue arrow indicates facial nerve.

In both temporal bones, the branching angle of the chorda tympani, the distance to the stylomastoid foramen and the distance between it and the facial nerve were compared; It was observed that there was a significant difference in the distance from the stylomastoid foramen. In other words, we can say that the chorda tympani which branches from the anterior, originates more distantly from the stylomastoid foramen.

This study has several limitations. First, the number of patients included in the study is small. The 16-slice CT we used in our study is a relatively old technology.

# CONCLUSION

Our study shows that the branching of the

chorda tympani from the facial nerve, its distance from the stylomastoid foramen, and the distance between it and the facial nerve vary in each patient. These differences may be due to differences in the aeration of mastoid cells. Finding the chorda tympani from a single image is difficult due to the complex anatomy of the mastoid bone. Taking a specific reference point, seeing the branching of the chorda tympani from the facial nerve, and following the chorda tympani makes it easier to detect and measure the nerve. Prospective studies with Ear Nose Throat surgeons will show in more detail the effectiveness of preoperative evaluation of chorda tympani with CT in reducing intraoperative chorda tympani damage.

# REFERENCES

- McManus LJ, Stringer MD, Dawes PJ. Iatrogenic injury of the chorda tympani: a systematic review. *J Laryngol Otol*. 2012;126(1):8–14.
- Choi N, Ahn J, Cho YS. Taste changes in patients with middle ear surgery by intraoperative manipulation of chorda tympani nerve. *Otol Neurotol*. 2018;39(5):591–6.
- Erovic BM, Chan HH, Daly MJ, Pothier DD, Yu E, Coulson C, et al. Intraoperative cone-beam computed tomography and multi-slice computed tomography in temporal bone imaging for surgical treatment. *Otolaryngol Head Neck Surg*. 2014;150(1):107–14.
- Singh D, Hsu CC, Kwan GN, Bhuta S, Skalski M, Jones R. High-resolution CT study of the chorda tympani nerve and normal anatomical variation. *Jpn J Radiol*. 2015;33(5):279–86.
- Parlier-Cuau C, Champsaur P, Perrin E, Rabischong P, Lassau JP. High-resolution computed tomography of the canals of the temporal bone: anatomic correlations. *Surg Radiol Anat*. 1998;20(6):437–44.
- Jeon EJ, Oh SH, Kim JH, Lee HS, Lee DS, Chung JW. Surgical and radiologic anatomy of a cochleostomy produced via posterior tympanotomy for cochlear implantation based on three-dimensional reconstructed temporal bone CT images. *Surg Radiol Anat*. 2013;35(6):471–5.
- Kim CW, Kwon OJ, Park JH, Park YH. Posterior tympanotomy is a riskier procedure in chronic otitis media than in a normal mastoid: a high-resolution computed tomography study. *Surg Radiol Anat*. 2016;38(6):717–21.
- Wang L, Yang H, Wu H, Jiang H. Cochlear implantation surgery in patients with narrow facial recess. *Acta Otorhinolaryngol Ital*. 2013;133(9):935–8.
- Fujita S, Nishizawa S, Yagihashi T, Tohma H. Postnatal developmental changes in facial nerve morphology. *Eur Arch Otorhinolaryngol*. 1994;251(7):434–8.
- Zou T, Xie N, Guo M, Shu F, Zhang H. [Title in original language]. *Lin Chuang Er Bi Yan Hou Tou Jing Wai Ke Za Zhi*. 2012;26(10):445–8.
- Low WK. Surgical anatomy of the facial nerve in Chinese mastoids. *ORL J Otorhinolaryngol Relat Spec*. 1999;61(6):341–4.
- Kulczyński B, Woźniak W. Variation of the origin and course of the chorda tympani. *Folia Morphol*. 1977;37(3):237–41.
- Muren C, Wadin K, Wilbrand HF. Anatomic variations of the chorda tympani canal. *Acta Otorhinolaryngol*. 1990;110(3–4):262–5.
- Kullman GL, Dyck PJ, Cody DTR. Anatomy of the mastoid portion of the facial nerve. *Arch Otolaryngol*. 1971;93(1):29–33.
- Calli C, Ugur MB, Onur E, Adanir S, Ozturk E, Karatas A, et al. Measurements of the facial recess anatomy: implications for sparing the facial nerve and chorda tympani during posterior tympanotomy. *Ear Nose Throat J*. 2010;89(10):490.
- Shin KJ, Lee SH, Kim SS, Kim SW, Kim JY, Cho JH, et al. Three-dimensional study of the facial canal using microcomputed tomography for improved anatomical comprehension. *Anat Rec*. 2014;297(10):1808–16.