

The evaluation of the protective effect of ambroxol against acetaminophen-induced hepatorenal toxicity in rats

Serkan SAYINER ^{1*} , Sevgi GENÇOSMAN ¹ , Hüseyin ŞAH ² , Nurhayat GÜLMEZ ³ , Ahmet Özer ŞEHİRLİ ⁴ 

¹ Department of Biochemistry, Faculty of Veterinary Medicine, Near East University, Nicosia, North Cyprus, Mersin-10 Türkiye.

² Department of Histology and Embryology, Faculty of Veterinary Medicine, Near East University, Nicosia, North Cyprus, Mersin-10 Türkiye.

³ Department of Histology and Embryology, Faculty of Veterinary Medicine, Siirt University, Siirt, Türkiye.

⁴ Department of Pharmacology, Faculty of Dentistry, Near East University, Nicosia, North Cyprus, Mersin-10 Türkiye.

* Corresponding Author. E-mail: serkan.sayiner@neu.edu.tr (S.S.); Tel. +90-392-675 10 00.

Received: 6 February 2024 / Revised: 12 March 2024 / Accepted: 14 March 2024

ABSTRACT: Acetaminophen (APAP), widely used as an analgesic-antipyretic drug, can cause liver and kidney damage at high doses. This study explored the protective effects of a mucolytic agent and an antioxidant Ambroxol (AMB), against APAP-induced toxicity in rats. The experiment included four groups of Wistar albino rats each having 6 animals in both sexes: a control group, an AMB-only group (50 mg/kg orally), an APAP-only group (1000 mg/kg intraperitoneally), and a combination APAP+AMB group. Twenty-four hours following the administration of APAP administration, rats were sacrificed. Measurements of blood levels of liver enzymes (AST, ALT, ALP, LDH), kidney function markers (Urea, Creatinine), and antioxidant enzymes (SOD, GPx) were performed. GPx and SOD activities were also assessed in hepatic and renal tissue samples. Histological examination of hepatic and renal tissues was conducted using Haematoxylin and Eosin staining. Results showed that APAP significantly increased liver enzymes, BUN, and Creatinine levels, indicating hepatorenal damage. This was accompanied by a decrease in plasma GPx and SOD activities. However, AMB treatment significantly mitigated these changes. It improved enzyme activities and increased hepatic GPx. Histologically, the APAP group showed liver cell damage, necrosis, haemorrhage, and inflammation, which were notably reduced in the AMB-treated group. This study suggests that Ambroxol effectively counters APAP-induced hepatorenal damage by restoring antioxidant enzyme levels and normalizing functional enzyme activities, highlighting its potential as a protective agent.

KEYWORDS: Acetaminophen; Ambroxol; Glutathione peroxidase; Superoxide dismutase; Liver; Kidney.

1. INTRODUCTION

Acetaminophen (APAP), a nonsteroidal anti-inflammatory drug, was discovered by Morse in 1878. [1]. APAP, also known as paracetamol, is widely used worldwide. It has antipyretic and analgesic properties [2]. While the therapeutic use of APAP at recommended doses generally does not cause adverse effects, it is noted to induce toxic effects in the liver and kidneys with high single-dose usage. Furthermore, it has been reported to contribute to liver and kidney toxicity with frequent use, even at therapeutic doses [3, 4].

Upon administration of therapeutic doses of APAP, an estimated 95% undergoes metabolic detoxification in hepatocytes, predominantly through glucuronidation and sulfation, leading to the generation of water-soluble metabolites subsequently excreted renally. The minor fraction, about 5%, is metabolized by hepatic microsomal enzymes, predominantly cytochrome P450 enzymes, resulting in the formation of the hepatotoxic metabolite NAPQI (N-acetyl-p-benzoquinone imine). NAPQI is usually detoxified by combining with hepatic glutathione (GSH) and is then excreted as mercapturic acid via biliary elimination [3, 5]. In instances of excessive APAP ingestion, the capacity of glucuronidation and sulfation pathways becomes overwhelmed, shifting the metabolic burden towards enhanced NAPQI production via the cytochrome P450 system. This change results in a swift reduction of the hepatic glutathione (GSH) stores. The subsequent decrease in glutathione peroxidase (GPx) activity leads to an escalation in intracellular

How to cite this article: Sayiner S, Gençosman S, Şah H, Gülmez N, Şehirli AÖ The evaluation of the protective effect of ambroxol against acetaminophen-induced hepatorenal toxicity in rats. J Res Pharm. 2024; 28(4): 1210-1219.

oxidative stress, marked by a rise in reactive oxygen species (ROS) production and a weakening of the cellular antioxidant defence systems [4, 6]. Furthermore, the impaired GPx activity, coupled with elevated levels of inflammatory cytokines, is implicated in the pathogenesis of hepatic necrosis [7].

Although less common than hepatotoxicity, high-dose APAP-induced nephrotoxicity can lead to more fatal consequences. Kidney failure can occur in approximately 2% of patients, and renal failure can manifest even without the development of liver failure [8, 9]. The toxic metabolite NAPQI, generated because of high-dose APAP metabolism in the liver, also contributes to renal damage [10]. Additionally, when APAP is taken at therapeutic doses, it undergoes deacetylation in the renal tissue, converting to p-aminophenol (PAP), then conjugated with GSH molecules and excreted in an inactive form. However, high doses of APAP deplete GSH molecules, leading to a decrease in GSH-peroxidase (GPx) activity and the accumulation of metabolites in the body. P-aminophenol metabolites cause cortical necrosis in the kidneys [9, 10]. Additionally, analogous to hepatic processes, the interaction of NAPQI metabolites with intracellular renal components, along with a reduction in glutathione peroxidase (GPx) and superoxide dismutase (SOD) activities, leads to escalated levels of reactive oxygen species (ROS). This increase in ROS contributes to renal injury [11]. To summarize, both hepatic and renal damages instigated by APAP are initially countered by intracellular antioxidants like GPx and SOD. Nevertheless, elevated doses of APAP result in the depletion of these antioxidant molecules, thereby initiating pathophysiological events [12].

Ambroxol (AMB) is a compound derived from the *Adhatoda vasica* plant. It possesses the chemical structure and exhibits mucolytic and expectorant properties, stimulating surfactant release from type II alveolar cells. AMB is frequently used in the management of acute or chronic respiratory disorders [13, 14]. Additionally, it is known to possess antioxidant and anti-inflammatory effects by suppressing free oxygen radicals [14-18].

The primary goal of this study was to evaluate the histomorphological protective effects of Ambroxol, a mucolytic drug, on hepatorenal damage caused by high APAP doses in a rat model. Moreover, the research sought to investigate the biochemical role of antioxidant enzymes, thereby elucidating the potential antioxidant properties of AMB.

2. RESULTS

In the blood analysis, there were no significant changes between the control and AMB groups for the parameters AST, ALT, ALP, LDH, BUN and Creatinine ($p > 0.05$) (Table 1). However, high dose of APAP resulted in a significant elevation in these parameters, with a significance ranging from $p < 0.01$ to $p < 0.001$. In contrast, subsequent treatment with AMB following APAP exposure led to a significant amelioration in these values, reflected by p-values between < 0.05 and < 0.01 .

Table 1. Serum chemistry parameters in all groups (Mean \pm SD).

	Control	AMB	APAP	APAP+AMB
AST (U/L)	11.8 \pm 4.4	39.8 \pm 9.2	93,3 \pm 28,5 ^{***, ++}	45,3 \pm 25,0 [∇]
ALT (U/L)	65.8 \pm 26.9	48.8 \pm 22.4	281,7 \pm 122,1 ^{***, +++}	137,7 \pm 64,6 [∇]
ALP (U/L)	144.9 \pm 27.3	180.1 \pm 99.8	1663,0 \pm 756,2 ^{***, ++}	832,0 \pm 29,1 ^{*, ∇}
LDH (U/L)	905.0 \pm 617.5	876.0 \pm 329.5	7942,0 \pm 3994,0 ^{***, +++}	2301,0 \pm 1473,0 ^{∇∇}
BUN (mg/dL)	56.7 \pm 10.8	68.7 \pm 14.6	169.5 \pm 17.7 ^{***, ++}	101.7 \pm 14.5 [∇]
Creatinine (mg/dL)	0.59 \pm 0.34	0.64 \pm 0.45	1.46 \pm 0.16 ^{**, ++}	0.88 \pm 0.21 [∇]

* $p < 0.05$, *** $p < 0.001$; compared to control group; ** $p < 0.01$; +++ $p < 0.001$ compared to AMB group; ∇ $p < 0.05$, ∇∇ $p < 0.01$; compared to APAP group.

Regarding the antioxidant enzymes, GPx and SOD activities were insignificantly different between the control and AMB groups ($p > 0.05$) (Figure 1). Yet, post-APAP administration, a marked decrease in their activities was observed in plasma, liver, and kidney tissues, compared to both control and AMB groups, with statistical significance ranging from $p < 0.05$ to $p < 0.01$. In the group APAP+AMB, these changes approximated the control group values, suggesting a mitigative effect, with p-values less than 0.05.

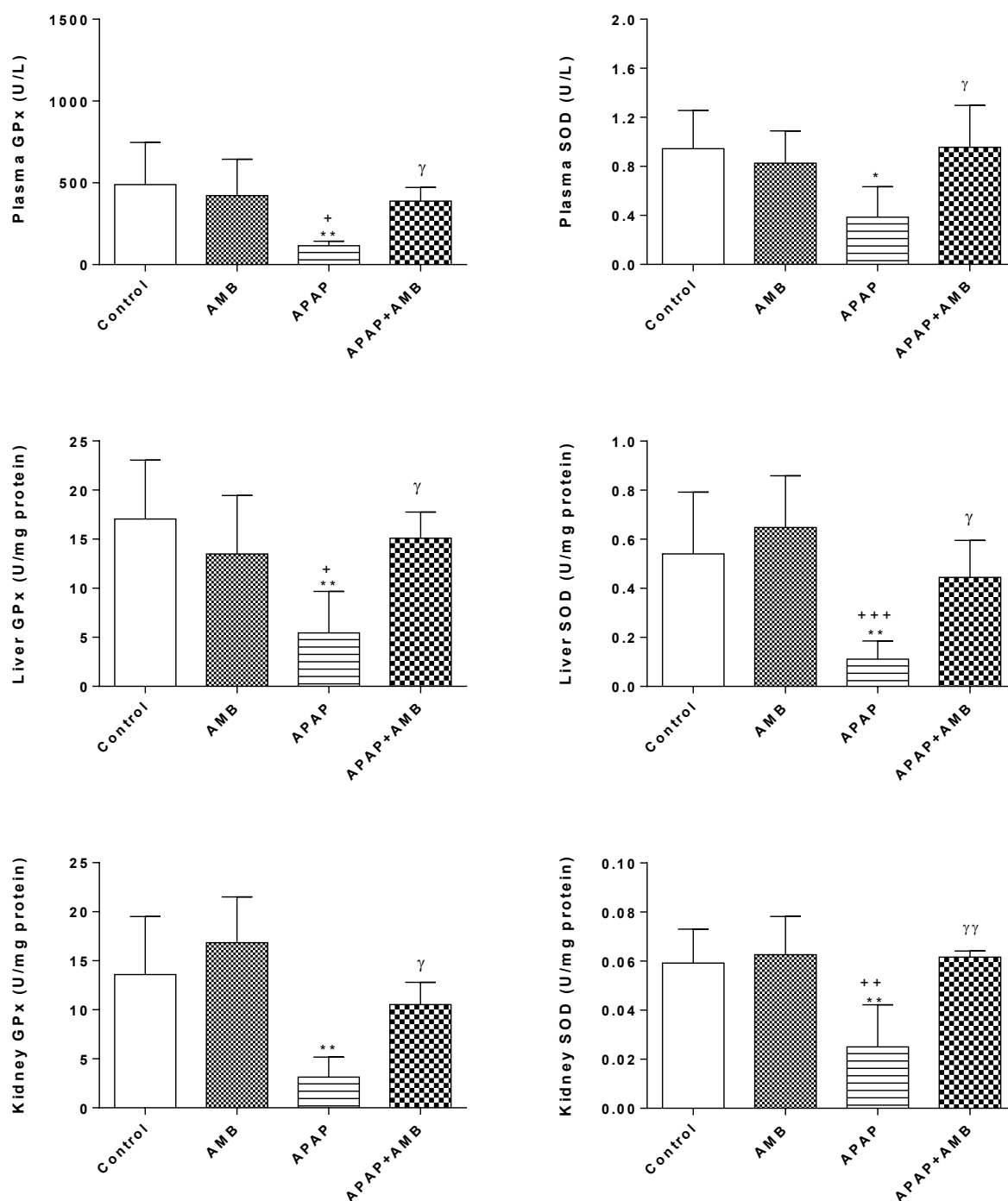


Figure 1. Plasma, liver and kidney GPx and SOD activities in all groups. $*p < 0.05$, $**p < 0.01$; compared with control group. $*p < 0.05$, $**p < 0.01$; $+++p < 0.001$ compared with AMB group. $γ p < 0.05$, $γγ p < 0.01$ compared with APAP group.

Upon examining the histopathological scoring results, hepatocytes displaying eosinophilic cytoplasm, karyopyknosis, congestion, and mononuclear cell infiltration were observed to be very rare in hepatic tissues in the control and AMB groups. Analysis of Table 2 revealed a significant statistical difference between these groups and the APAP and APAP+AMB groups, with p-values less than 0.05. Notably, necrosis was absent in the liver tissues of the control and Ambroxol groups. A statistically significant difference was observed in terms of necrosis when comparing these groups with the APAP group ($p < 0.05$).

Significant liver degeneration was observed in APAP group compared to the control and AMB groups. However, in the APAP+AMB group, the extent of degeneration was reduced relative to the APAP group, although it did not revert to the levels observed in the control groups. A significant difference between the APAP+AMB and APAP groups concerning the scores for cells with eosinophilic cytoplasm, karyopyknosis, congestion, and mononuclear cell infiltration were determined ($p<0.05$). While necrosis was less pronounced in the APAP+AMB group compared to the APAP group ($p>0.05$).

When examining the renal histological scoring results in Table 3, a statistical difference was detected between the control and ambroxol groups versus the APAP and APAP+AMB groups in terms of mononuclear cell infiltration, tubular, and glomerular damage ($p<0.05$). However, no significant difference was found between the ambroxol group and the APAP+AMB group alone ($p>0.05$). Histological changes, particularly degeneration, were most prominently observed in the APAP group. Significance between the APAP and APAP+AMB groups was only found in the criterion of tubular damage ($p<0.05$). Despite the reduction in glomerular damage and mononuclear cell infiltration, no statistical difference was observed between the APAP and APAP+AMB groups ($p>0.05$).

Table 2. Hepatic histomorphologic scoring results of the groups.

Scores of hepatic histomorphological measurements.					
Groups	Eosinophilic cytoplasm	Karyopyknosis	Necrose	Congestion	Mononuclear cell infiltrations
Control	0,033±0,051 ^{a,b}	0,033±0,051 ^{f,g}	0,000±0,000 ^k	0,000±0,000 ^{o,p}	0,066±0,081 ^{u,v}
AMB	0,050±0,054 ^{c,d}	0,033±0,051 ^{h,i}	0,000±0,000 ^l	0,033±0,081 ^{r,s}	0,083±0,098 ^{w,x}
APAP	0,933±0,480 ^{a,c,e}	0,850±0,463 ^{f,h,j}	0,150±0,151 ^{k,l}	0,383±0,116 ^{o,r,t}	1,000±0,275 ^{u,w,y}
APAP+AMB	0,466±0,150 ^{b,d,e}	0,350±0,104 ^{g,i,j}	0,050±0,054	0,216±0,098 ^{p,s,t}	0,466±0,216 ^{v,x,y}
P Value	0,000***	0,000***	0,016*	0,000***	0,000***

*The degree of statistical significance of the Kruskal Wallis test results. The same letter ^{a-y} represents statistically significant results between the groups at the level of $p<0.05$.

Table 3. Histomorphologic scoring results in renal tissues of the groups

Scores of renal tissues histomorphological measurements.			
Groups	Tubular damage	Glomerular damage	Mononuclear cell infiltrations
Control	0,066±0,081 ^{a,b}	0,066±0,081 ^{f,g}	0,066±0,081 ^{j,k}
AMB	0,083±0,098 ^{c,d}	0,083±0,098 ^{h,i}	0,133±0,121 ^l
APAP	1,050±0,151 ^{a,c,e}	1,283±0,376 ^{f,h}	0,766±0,242 ^{j,l}
APAP+AMB	0,783±0,075 ^{b,d,e}	0,916±0,147 ^{g,i}	0,416±0,292 ^k
P Value	0,000***	0,001**	0,003**

*The degree of statistical significance of the Kruskal Wallis test results. The same letter^{a-l} represents statistically significant results between the groups at the level of $p<0.05$.

Light microscopic examination revealed a normal histological structure in the liver tissues of the control and Ambroxol groups, as depicted in Figure 2A and 2B. In the Ambroxol group, there was a noted presence of mild congestion within the sinusoids (Figure 2B). In contrast, the liver tissues from the APAP group exhibited pronounced pathological changes including intense mononuclear cell infiltration, hepatocytes with karyopyknotic and eosinophilic cytoplasm, marked congestion, and extensive necrosis in the sinusoids, as shown in Figures 2C, 2D, and 2E. Despite the severity of these changes in the APAP group, a comparative reduction in histological abnormalities was observed in the APAP+AMB group. This group, represented in Figure 2F, showed a decrease in the extent of histological changes. However, it was noted that mononuclear cell infiltration and alterations in hepatocyte structure persisted, albeit to a lesser degree than observed in the APAP-only group.

Light microscopy was employed to examine the renal structures in the various groups. In the control and Ambroxol groups, the renal histology appeared normal, as shown in Figures 3A and 3B. However, a stark contrast was observed in the APAP group, where significant histological alterations were evident. These included substantial infiltration of mononuclear cells, disruption in the structure of tubular epithelial cells, and notable vacuolization accompanied by enlargement in the cytoplasm of some cells, as detailed in Figure 3C. In the group treated with both APAP and Ambroxol (APAP+AMB group), a comparative improvement in renal histology was noted. This was evidenced by a decrease in the number of mononuclear cells, reduced congestion in the intertubular capillaries, and a lesser degree of vacuolization in the tubule epithelial cells, in comparison to the APAP group. These findings, depicted in Figure 3D, suggest a mitigative effect of Ambroxol on APAP-induced renal damage.

3. DISCUSSION

The purpose of this study was to determine the protective impact of Ambroxol on rats exposed to high dosages of APAP. To this end, blood levels of liver function enzymes (ALT, AST, LDH, ALP), kidney function markers (BUN and Creatinine), and the activities of the antioxidant enzymes (GPx and SOD) in plasma, liver, and kidney tissues were detected and evaluated. Furthermore, the study involved a histomorphological examination to evaluate the structural damage in hepatic and liver tissues caused by APAP, employing Haematoxylin and Eosin staining. Our findings revealed that administration of APAP alone had a detrimental effect on both biochemical and histomorphological parameters in liver and kidney tissues. Notably, these adverse changes were significantly ameliorated following the administration of Ambroxol (AMB), indicating its potential protective efficacy against APAP-induced damage.

In terms of liver and kidney function tests, AST, ALT, BUN, and creatinine levels were measured, as well as ALP and LDH activities, which are regarded indications of inflammation or tissue damage [19, 20]. It has been shown in experimental and clinical studies that APAP administration leads to a significant increase in ALP and LDH activities, accompanied by structural damage [19, 21]. Our findings are consistent with the literature. Ambroxol, used as a protective agent, has demonstrated beneficial effects on AST, ALT, BUN, and Creatinine levels in previous studies, but its effects on LDH and ALP activities have not been evaluated in the context of APAP toxicity until now. Our study provides novel insights in this regard. The results of our study are consistent with previous studies on AMB's effects on liver and kidney function tests. The reduction in LDH and ALP activities is particularly important as it indicates a protective effect.

We evaluated the activities of GPx and SOD, known for their protective effects against oxidative damage in our body, in APAP toxicity. It is well known that excessive glutathione consumption leads to persistent damage in both the liver and kidney. Studies have shown that this consumption also affects and decreases GPx activity [22, 23]. The studies on the effects of SOD in APAP toxicity are increasing day by day. It has been demonstrated that SOD activities decrease in hepatorenal damage caused by APAP [24-26]. In our study, the decrease in GPx and SOD activities in plasma, liver, and kidney tissues following high-dose APAP administration, in line with the literature, was histomorphologically shown to contribute to hepatorenal damage. Previous studies on Ambroxol have shown an increase in GPx activity only in inflammation models conducted on the lungs [27, 28], and there is no study evaluating its effect on GPx in plasma, liver, and kidney tissues. Therefore, our study is the first to demonstrate the effect of Ambroxol on GPx activity in these tissues. However, when considering the overall results, the positive effects of Ambroxol observed in our study align with its positive effects reported in different tissues. The effects of Ambroxol on SOD activity have been evaluated in various tissues in different inflammation models [14] and our results are in line with the findings of those studies.

APAP caused significant histomorphological changes in liver and kidney tissues. Consistent with our findings, Ebada (2018) induced liver damage in rats with APAP and detected light microscopic findings of hepatocyte degeneration, necrosis, congestion, haemorrhage, and mononuclear cell infiltration [29]. The effect of APAP on kidney tissue was mostly on tubular, glomerular damage, and mononuclear cell infiltration. Studies by Reshi et al., (2017) and Ko et al., (2017) support our findings [30, 31]. Ambroxol was effective in alleviating APAP-induced liver and kidney damage. Consistent with our findings, the light microscopic healing effects of ambroxol were demonstrated in ischemia and reperfusion studies in liver and kidney tissues [16, 32].

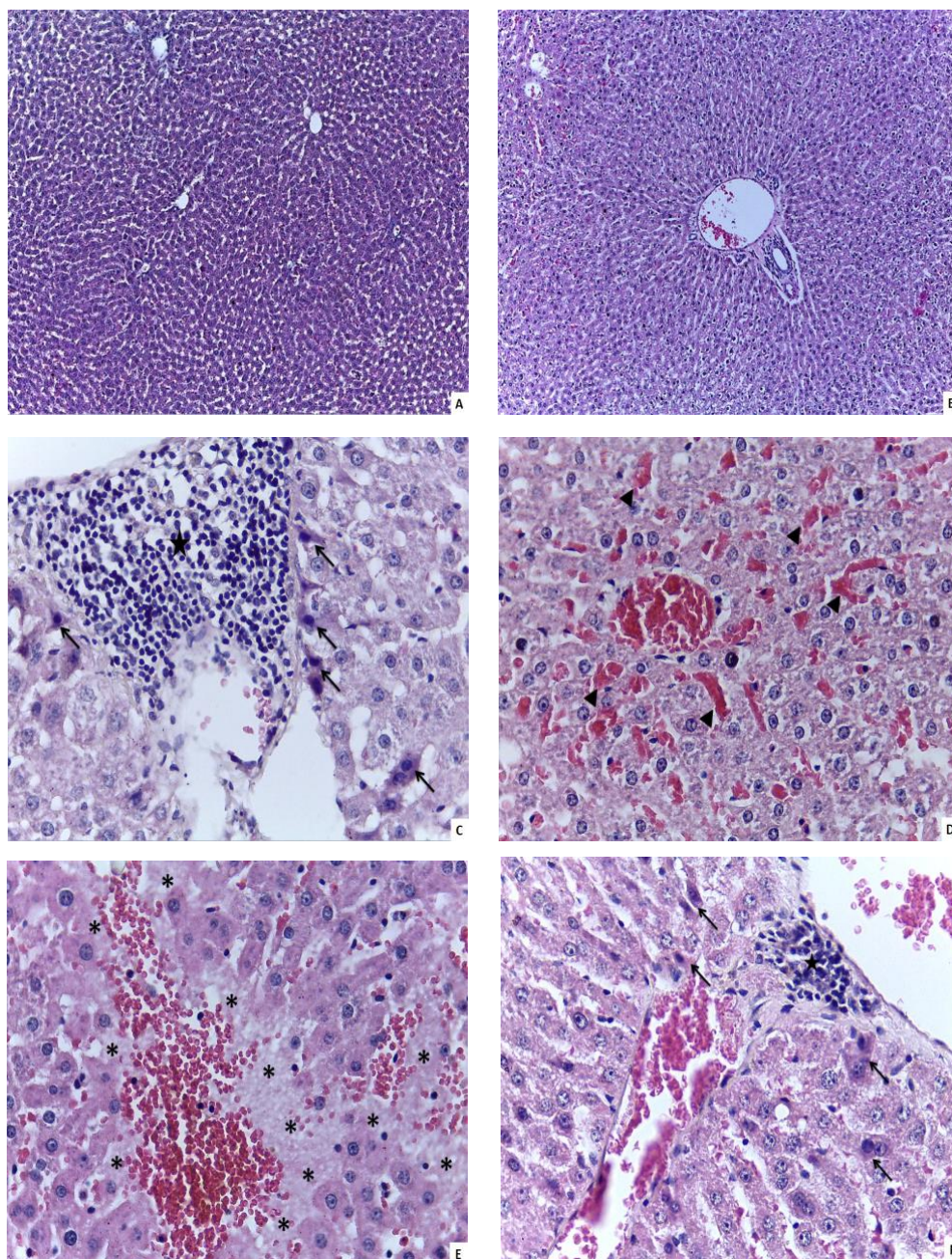


Figure 2. Light microscopic view of liver tissue from control (A), ambroxol (B), APAP (C - D - E) and APAP + ambroxol (F) groups. Figures A and B show normal liver structure (x100). Figure C shows dense mononuclear cell infiltration (★), cells with eosinophilic cytoplasm and karyoplastic nuclei (→); figure D shows haemorrhage (►) and figure E shows necrosis area (*) (x400). Figure F shows reduced mononuclear cell infiltration (★) and cells with eosinophilic cytoplasm and karyophilic nuclei (→) (x400). Haematoxylin & eosin staining.

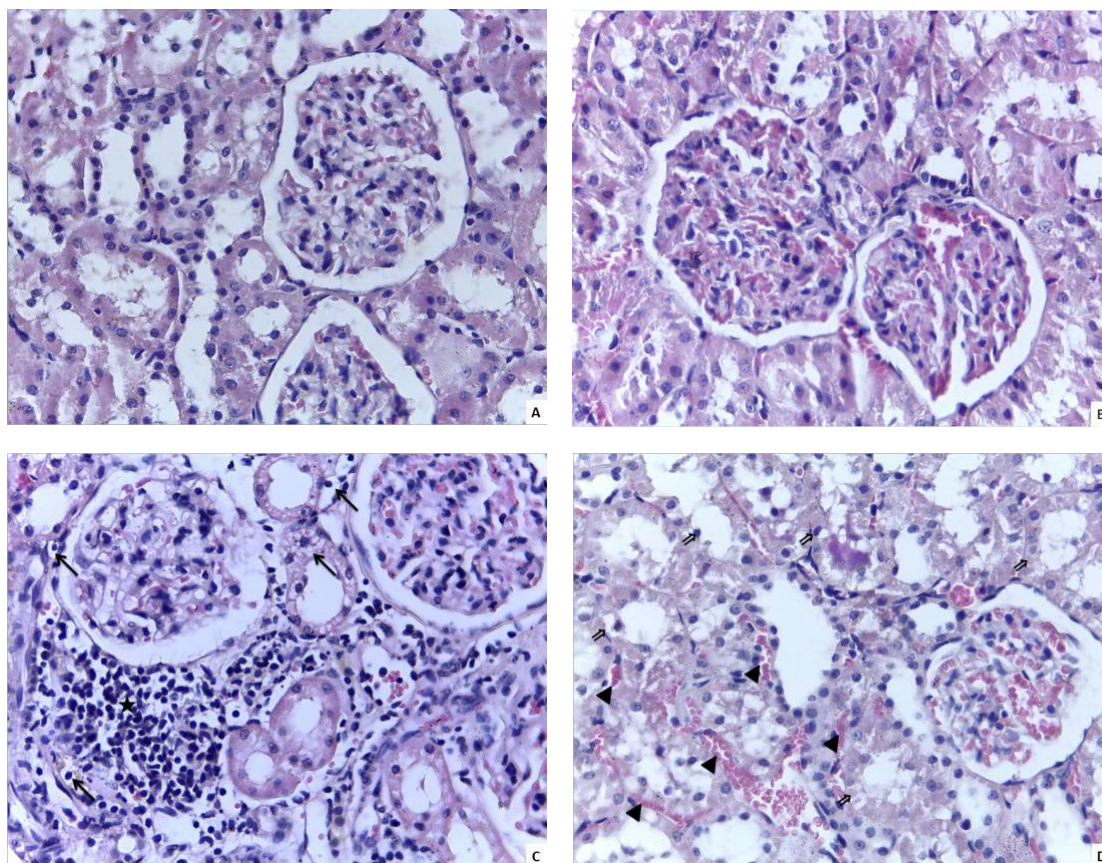


Figure 3. Light microscopy images of the kidneys from four groups were examined: control (A), Ambroxol (B), APAP (C), and APAP+Ambroxol (D). Figures A and B illustrate normal kidney structure, while Figure C displays dense mononuclear cell infiltration (★) and vacuolization (→) in cells. Figure D shows vacuolization (↗) and capillary fullness (►) in tubule epithelial cells (at a magnification of 400 times). Haematoxylin and eosin staining was used to prepare the images.

4. CONCLUSION

One of the most significant factors that restrict the treatment of high-dose APAP, which is considered safe in pregnant women and children, is its potential to cause hepatorenal damage. To prevent permanent damage in liver and kidney tissues during the development of such toxicity, the use of drugs with antioxidant properties is of great importance. Considering that APAP is commonly used as an analgesic and antipyretic agent, it is plausible that antioxidant agents with mucus-clearing properties, such as ambroxol, could be used not only in terms of toxicity but also as adjunctive agents in treatment.

5. MATERIALS AND METHODS

5.1. Animals

In this research, adult Wistar albino rats from both genders, each weighing between 200-250 grams, were utilized. These rats were bred and raised at the Near East University Animal Research Center and housed in a controlled environment with a 12-hour light-dark cycle, at 22°C. The rats had free access to water and a standard pellet diet throughout the study. Ethical compliance was a priority; thus, the study adhered to established ethical guidelines and received approval from the Near East University Local Ethics Committee for Animal Experiments, under the Approval No: 56-2019/01.

5.2. Chemicals

In our study, the chemical agent we used to evaluate its toxic effects is APAP. The chemical agent we selected, considering its potential protective effect against APAP, is ambroxol hydrochloride. The drug doses

used for the subjects were determined based on the following studies. APAP was administered at a dose of 1000 mg/kg [33]; AMB hydrochloride was administered at a dose of 50 mg/kg [34].

5.3. Experimental Design

The rats were allocated into four groups of six each. Group 1 was the control group; 0.9% saline solution was administrated intraperitoneally. Group 2, AMB group, received AMB hydrochloride at a dose of 50 mg/kg via oral gavage. Group 3, APAP group received intraperitoneal administration of APAP at a dose of 1000 mg/kg. Group 4, APAP+AMB group, received a combination of oral gavage of AMB hydrochloride at a dose of 50 mg/kg and intraperitoneal administration of APAP at a dose of 1000 mg/kg. Each chemical substances were administered to the rats in a single dose, and the experiment was terminated after 24 hours. Prior to sacrifice, the rats were anesthetized by intraperitoneal administration of xylazine (10 mg/kg) and ketamine (100 mg/kg). Intracardiac blood samples were collected from all rats using both serum separator tubes and tubes containing EDTA. Subsequently, the rats were sacrificed, and hepatic and renal tissues were collected for both biochemical and histomorphological examination.

5.4. Biochemical Analyses

Plasma enzyme activities, including AST, ALT, ALP, LDH, SOD, and GPx, along with urea and creatinine levels, were quantified using commercially available assay kits (Randox, County Antrim, UK and Mindray Chemistry Reagents, Shenzhen, China). Liver and kidney tissues were homogenized following the method outlined by Baluchamy et al. [35], enabling the measurement of GPx and SOD activities. These biochemical analyses were conducted using an automated clinical chemistry analyzer (BS120, Mindray), which facilitated the quantification of enzyme activities and other biological markers.

5.5. Histomorphological Examination

Hepatic and renal tissues were placed in 10% formalin solution and kept at room temperature for 24 hours. After fixation, the tissues were embedded in paraffin using a tissue processor (Leica TP1020) and then embedded in paraffin blocks using a paraffin embedding system (Leica EG1150). Subsequently, 5-micron thick sections were obtained from each tissue using a microtome (Leica RM2255). The tissue sections on slides were stained with haematoxylin and eosin after deparaffinization and then covered with coverslips. Histomorphological examination of each tissue section was performed under a light microscope (Leica DM500). The evaluation of liver tissue sections was conducted using the liver scoring system employed by Ciftci et al. (2017) [36]. According to this scoring system, each liver tissue section was assessed for eosinophilic cytoplasmic hepatocytes, karyopyknotic hepatocytes, necrosis, congestion, and mononuclear cell infiltration. The extent of damage in 10 different fields for each criterion was graded as absent (0), mild (1), moderate (2), or severe (3) [36-39]. The evaluation of kidney tissue sections was performed in a similar manner to the liver tissue. The kidney tissue was assessed for mononuclear cell infiltration, tubular and glomerular damage. Ten regions were scanned for each criterion, and the extent of damage in each region was graded as absent (0), mild (1), moderate (2), or severe (3) [36-39].

5.6. Statistical analysis

Data analysis was conducted using GraphPad Prism 6.0 (GraphPad Software, San Diego, CA, USA). Results were expressed as mean \pm standard deviation (Mean \pm SD). Biochemical data were analysed using analysis of variance (ANOVA), followed by post hoc Tukey's multiple comparison tests for detailed pairwise comparisons. For the histomorphological data, initial comparisons were made using the Kruskal-Wallis test, followed by the Mann-Whitney U test for specific group comparisons. A p-value of less than 0.05 was considered statistically significant.

Acknowledgements: This research was partially presented in an oral format at the 2nd International Conference on Veterinary Biochemistry & Clinical Biochemistry, held from October 24 to 26, 2019, in Ankara, Turkey.

Author contributions: Concept – S.S., A.Ö.Ş.; Design – S.S., A.Ö.Ş.; Supervision – S.S., A.Ö.Ş.; Resources – S.S., A.Ö.Ş.; Materials – S.S., A.Ö.Ş, S.G., H.Ş., N.G.; Data Collection and/or Processing – S.S., A.Ö.Ş, S.G., H.Ş.; Analysis and/or Interpretation – S.S., A.Ö.Ş, S.G., H.Ş, N.G.; Literature Search – S.S., A.Ö.Ş, S.G., H.Ş, N.G.; Writing – S.S, A.Ö.Ş., S.G., H.Ş.; Critical Reviews – S.S., A.Ö.Ş, S.G., H.Ş., N.G.

Conflict of interest statement: The authors declare no conflict of interest.

REFERENCES

- [1] Wang X, Wu Q, Liu A, Anadón A, Rodríguez JL, Martínez-Larrañaga MR, Yuan Z, Martínez MA. Paracetamol: overdose-induced oxidative stress toxicity, metabolism, and protective effects of various compounds in vivo and in vitro. *Drug Metab Rev.* 49 (4): 395-437. <https://doi.org/10.1080/03602532.2017.1354014>
- [2] Tittarelli R, Pellegrini M, Scarpellini MG, Marinelli E, Bruti V, Luca NM Di, Busardò FP, Zaami S. Hepatotoxicity of paracetamol and related fatalities. *Eur Rev Med Pharmacol Sci.* 2017; 21 (1): 95-101.
- [3] Abdeen A, Abdelkader A, Abdo M, Wareth G, Aboubakr M, Aleya L, Abdel-Daim M. Protective effect of cinnamon against acetaminophen-mediated cellular damage and apoptosis in renal tissue. *Environ Sci Pollut Res.* 2019; 26 (1): 240-249. <https://doi.org/10.1007/s11356-018-3553-2>
- [4] Wang Z, Hu JN, Yan MH, Xing JJ, Liu WC, Li W. Caspase-mediated anti-apoptotic effect of ginsenoside Rg5, a main rare ginsenoside, on acetaminophen-induced hepatotoxicity in mice. *J Agric Food Chem.* 2017; 65 (42): 9226-9236. <https://doi.org/10.1021/acs.jafc.7b03361>
- [5] Murad HAS, Habib H, Kamel Y, Alsayed S, Shakweer M, Elshal M. Thearubigins protect against acetaminophen-induced hepatic and renal injury in mice: Biochemical, histopathological, immunohistochemical, and flow cytometry study. *Drug Chem Toxicol.* 2016; 39 (2): 190-198. <https://doi.org/10.3109/01480545.2015.1070170>
- [6] Uzkeser M, Karakus E, Albayrak A, Kiki İ, Bayir Y, Cadirci E, Unal D, Halici Z, Karadeniz A. Protective effect of Panax ginseng against N-acetyl-p-aminophenol-induced hepatotoxicity in rats. *Afr J Pharm Pharmacol.* 2012; 6 (36): 2634-2642. <https://doi.org/10.5897/AJPP12.658>
- [7] Jothy SL, Aziz A, Chen Y, Sasidharan S. Antioxidant activity and hepatoprotective potential of Polyalthia longifolia and Cassia spectabilis leaves against paracetamol-induced liver injury. *Evid Based Complement Alternat Med.* 2012;2012:561284. <https://doi.org/10.1155/2012/561284>
- [8] Ghosh J, Das J, Manna P, Sil PC. Acetaminophen induced renal injury via oxidative stress and TNF- α production: Therapeutic potential of arjunolic acid. *Toxicology.* 2010; 268 (1-2): 8-18. <https://doi.org/10.1016/j.tox.2009.11.011>
- [9] Ozatik FY, Teksen Y, Kadioglu E, Ozatik O, Bayat Z. Effects of hydrogen sulfide on acetaminophen-induced acute renal toxicity in rats. *Int Urol Nephrol.* 2019; 51 (4): 745-754. <https://doi.org/10.1007/s11255-018-2053-0>
- [10] Mugford CA, Tarloff JB. The contribution of oxidation and deacetylation to acetaminophen nephrotoxicity in female Sprague-Dawley rats. *Toxicol Lett.* 1997; 93 (1): 15-22. [https://doi.org/10.1016/S0378-4274\(97\)00063-5](https://doi.org/10.1016/S0378-4274(97)00063-5)
- [11] Isik B, Bayrak R, Akcay A, Sogut S. Erdosteine against acetaminophen induced renal toxicity. *Mol Cell Biochem.* 2006; 287 (1-2): 185-191. <https://doi.org/10.1007/s11010-005-9110-6>
- [12] Azarmehr N, Afshar P, Moradi M, Sadeghi H, Sadeghi H, Alipoor B, Khalvati B, Barmoudeh Z, Abbaszadeh-Goudarzi K, Doustimotlagh AH. Hepatoprotective and antioxidant activity of watercress extract on acetaminophen-induced hepatotoxicity in rats. *Heliyon.* 2019; 5 (7): e02072. <https://doi.org/10.1016/j.heliyon.2019.e02072>
- [13] Cazan D, Klimek L, Sperl A, Plomer M, Kölsch S. Safety of ambroxol in the treatment of airway diseases in adult patients. *Expert Opin Drug Saf.* 2018; 17 (12): 1211-1224. <https://doi.org/10.1080/14740338.2018.1533954>
- [14] Sunkari S, Thatikonda S, Pooladanda V, Challa VS, Godugu C. Protective effects of ambroxol in psoriasis like skin inflammation: Exploration of possible mechanisms. *Int Immunopharmacol.* 2019; 71 301-312. <https://doi.org/10.1016/j.intimp.2019.03.035>
- [15] Gültekin Ç, Sayiner S, Çetinel Ş, Şehirli AÖ. Does Ambroxol alleviate kidney ischemia-reperfusion injury in rats? *Iran J Basic Med Sci.* 2022; 25 (8): 1037-1041. <https://doi.org/10.22038/IJBMS.2022.64330.14148>
- [16] Gultekin C, Sehirli AO, Cetinel S, Sayiner S. Could Ambroxol reduce cytokines in hepatic ischemia-reperfusion injury in rats? *Bratisl Lek Listy.* 2022; 123 (5): 381-384. <https://doi.org/10.4149/BLL.2022.060>
- [17] Nowak D, Antczak A, Król M, Bialasiewicz P, Pietras T. Antioxidant properties of ambroxol. *Free Radic Biol Med.* 1994; 16 (4): 517-522. [https://doi.org/10.1016/0891-5849\(94\)90130-9](https://doi.org/10.1016/0891-5849(94)90130-9)
- [18] Zhi QM, Yang LT, Sun HC. Protective effect of ambroxol against paraquat-induced pulmonary fibrosis in rats. *Intern Med.* 2011; 50 (18): 1879-1887. <https://doi.org/10.2169/internalmedicine.50.5407>
- [19] Fersahoğlu MM, Özkan E, Velioglu-Ögünç A, Sayiner S, Ercan F, Çilingir Kaya ÖT, Şehirli AÖ. Impact of pycnogenol on acetaminophen-induced hepatorenal damage. *Biointerface Res Appl Chem.* 2022; 12 (6): 8070-8080. <https://doi.org/10.33263/BRIAC126.80708080>
- [20] Sener G, Omurtag GZ, Sehirli O, Tozan A, Yüksel M, Ercan F, Gedik N. Protective effects of Ginkgo biloba against acetaminophen-induced toxicity in mice. *Mol Cell Biochem.* 2006; 283 (1-2): 39-45. <https://doi.org/10.1007/s11010-006-2268-8>
- [21] Sener G, Sehirli O, Cetinel S, Yeğen BG, Gedik N, Ayanoglu-Dülger G. Protective effects of MESNA (2-mercaptoethane sulphonate) against acetaminophen-induced hepatorenal oxidative damage in mice. *J Appl Toxicol.* 2005; 25 (1): 20-29. <https://doi.org/10.1002/jat.1012>
- [22] Li J, Gao Y, Cui L, He H, Zheng J, Mo S, Zhou X, Chu S, Sun X, Chen N, Wang H. Combination of monoammonium glycyrrhizinate and cysteine hydrochloride protects mice against acetaminophen-induced liver injury via Keap1/Nrf2/ARE pathway. *J Pharm Pharmacol.* 2022; 74 (5): 730-739. <https://doi.org/10.1093/jpp/rgab180>
- [23] Wang K, Yang L, Zhou J, Pan X, He Z, Liu J, Zhang Y. Smilax china L. Polysaccharide Alleviates Oxidative Stress and Protects From Acetaminophen-Induced Hepatotoxicity via Activating the Nrf2-ARE Pathway. *Front Pharmacol.* 2022; 13 888560. <https://doi.org/10.3389/fphar.2022.888560>

- [24] Dong K, Zhang M, Liu Y, Gao X, Wu X, Shi D, Guo C, Wang J. Pterostilbene-loaded soluplus/poloxamer 188 mixed micelles for protection against acetaminophen-induced acute liver injury. *Mol Pharm*. 2023; 20 (2): 1189–1201. <https://doi.org/10.1021/acs.molpharmaceut.2c00881>
- [25] Hammad AM, Shawaqfeh B, Hikmat S, Al-Qirim T, Hamadneh L, Al-Kouz S, Awad MM, Hall FS. The role of vitamin e in protecting against oxidative stress, inflammation, and the neurotoxic effects of acute paracetamol in pregnant female rats. *Toxics*. 2023; 11 (4): 368. <https://doi.org/10.3390/toxics11040368>
- [26] Koç A, Gazi M, Caner Sayar A, Onk D, Ali Arı M, Süleyman B, Gökhan Ağgöl A, Altındağ F, Altuner D, Süleyman H. Molecular mechanism of the protective effect of adenosine triphosphate against paracetamol-induced liver toxicity in rats. *Gen Physiol Biophys*. 2023; 42 (2): 201–208. <https://doi.org/10.4149/gpb.2022055>
- [27] Gupta PR. Ambroxol hydrochloride in the management of idiopathic pulmonary fibrosis: Clinical trials are the need of the hour. *Lung India*. 2014; 31 (1): 43–46. <https://doi.org/10.4103/0970-2113.125899>
- [28] Wang Y, Wang F-Y, Pan Z, Dai Y-Y, Xu H-J, Jin K-K, Wang W-T. Effects of ambroxol combined with low-dose heparin on TNF-alpha and IL-1beta in rabbits with acute lung injury. *Chin J Appl Physiol*. 2011; 27 (2): 231–235.
- [29] Ebada ME. Essential oils of green cumin and chamomile partially protect against acute acetaminophen hepatotoxicity in rats. *An Acad Bras Cienc*. 2018; 90 (2 suppl 1): 2347–2358. <https://doi.org/10.1590/0001-3765201820170825>
- [30] Ko J-W, Shin J-Y, Kim J-W, Park S-H, Shin N-R, Lee I-C, Shin I-S, Moon C, Kim S-H, Kim S-H, Kim J-C. Protective effects of diallyl disulfide against acetaminophen-induced nephrotoxicity: A possible role of CYP2E1 and NF-κB. *Food Chem Toxicol*. 2017; 102 156–165. <https://doi.org/10.1016/j.fct.2017.02.021>
- [31] Reshi MS, Shrivastava S, Jaswal A, Sinha N, Uthra C, Shukla S. Gold nanoparticles ameliorate acetaminophen induced hepato-renal injury in rats. *Exp Toxicol Pathol*. 2017; 69 (4): 231–240. <https://doi.org/10.1016/j.etp.2017.01.009>
- [32] Jiang K, Wang X, Mao X, Lao H, Zhang J, Wang G, Cao Y, Tong I, Zhang F. Ambroxol alleviates hepatic ischemia reperfusion injury by antioxidant and antiapoptotic pathways. *Transplant Proc*. 2013; 45 (6): 2439–2445. <https://doi.org/10.1016/j.transproceed.2013.04.007>
- [33] Elbe H, Gul M, Cetin A, Taslidere E, Ozyalin F, Turkoz Y, Oflu A. Resveratrol reduces light and electron microscopic changes in acetaminophen-induced hepatotoxicity in rats: Role of iNOS expression. *Ultrastruct Pathol*. 2018; 42(1): 39–48. <https://doi.org/10.1080/01913123.2017.1374313>
- [34] Zhao SP, Guo QL, Wang RK, Wang E. Oxidative and anti-oxidative effects of ambroxol on acute hydrochloric acid-induced lung injury in rats. *Zhong Nan Da Xue Xue Bao Yi Xue Ban*. 2004; 29 (5): 586–588.
- [35] Baluchamy S, Ravichandran P, Periyakaruppan A, Ramesh V, Hall JC, Zhang Y, Jejelowo O, Gridley DS, Wu H, Ramesh GT. Induction of cell death through alteration of oxidants and antioxidants in lung epithelial cells exposed to high energy protons. *J Biol Chem*. 2010; 285 (32): 24769–24774. <https://doi.org/10.1074/jbc.M110.138099>
- [36] Ciftci O, Onat E, Cetin A. The beneficial effects of fish oil following cisplatin-induced oxidative and histological damage in liver of rats. *Iran J Pharm Res*. 2017; 16 (4): 1424–1431.
- [37] Aykaç A, Şah H, Kükner A, Sayiner S, Şehirli AÖ. Effects of chitosan on cisplatin-induced hepatorenal toxicity in an animal model. *Istanbul Med J*. 2022; 23 (3): 183–188. <https://doi.org/10.4274/imj.galenos.2022.54077>
- [38] Moneim LMA, Helmy MW, El-Abhar HS. Co-targeting of endothelin-A and vitamin D receptors: a novel strategy to ameliorate cisplatin-induced nephrotoxicity. *Pharmacol Reports*. 2019; 71 (5): 917–925. <https://doi.org/10.1016/j.pharep.2019.04.018>
- [39] Şah H, Gülmez N, Söyler G, Sayiner S, Şehirli AÖ, Kükner A. Effect of kefir on increased apoptosis in liver and kidney in cisplatin toxicity. *Int J Morphol*. 2022; 40 (2): 480–488.