

Assessment of Alveolar Bone Loss and Buccal Bone Thickness After Surgically Assisted Rapid Maxillary Expansion

Cerrahi Destekli Hızlı Üst Çene Genişletmesi Sonrası Alveolar Kemik Kaybının ve Bukkal Kemik Kalınlığının Değerlendirilmesi

● Çağrı Esen¹, ● Alparslan Esen², ● Arif Yiğit Güler², ● Dilek Menziletoğlu², ● Ahmet Ertan Soğancı³

¹Nevşehir Hacı Bektaş Veli University Faculty of Dentistry, Department of Periodontology, Nevşehir, Turkey

²Necmettin Erbakan University Faculty of Dentistry, Department of Oral and Maxillofacial Surgery, Konya, Turkey

³Necmettin Erbakan University Faculty of Dentistry, Department of Orthodontics, Konya, Turkey



Keywords

Alveolar bone loss, cone-beam computed tomography, palatal expansion technique

Anahtar Kelimeler

Alveolar kemik kaybı, konik ışınli bilgisayarlı tomografi, palatal ekspansiyon tekniği

Received/Geliş Tarihi : 07.09.2020

Accepted/Kabul Tarihi : 23.12.2020

doi:10.4274/meandros.galenos.2020.97752

Address for Correspondence/Yazışma Adresi:

Çağrı Esen DDS PhD,
Nevşehir Hacı Bektaş Veli University Faculty of Dentistry, Department of Periodontology, Nevşehir, Turkey

Phone : +90 532 171 86 83

E-mail : cagriesen@hotmail.com

ORCID ID: orcid.org/0000-0002-4358-1293

©Meandros Medical and Dental Journal, Published by Galenos Publishing House.

This is article distributed under the terms of the Creative Commons Attribution NonCommercial 4.0 International Licence (CC BY-NC 4.0).

Abstract

Objective: The aim of this retrospective study was to evaluate the changes in alveolar bone height (ABH) and buccal bone thickness (BBT) of the maxillary teeth after surgically assisted rapid maxillary expansion (SARME) using cone-beam computed tomography (CBCT).

Materials and Methods: A total of 9 patients with preoperative and postoperative CBCT records were included in this study. All patients underwent SARME and all of them received a modified acrylic bonded appliance as a maxillary expander. CBCT images were taken before SARME (T1) and after a consolidation period of 3 to 4 months (T2). ABH was determined by measuring the distance from the cemento-enamel junction to the alveolar crest on CBCT images. To evaluate BBT, two different points were identified along the root surface.

Results: Alveolar bone loss (ABL) detected between T1 and T2 ABH measurements was statistically significant at all sites of each tooth. There was a statistically significant decrease in BBT at all measured points of each tooth between the T1 and T2 measurements.

Conclusion: SARME with modified acrylic-bonded appliances causes ABL and a decrease in BBT, which increases the risk of tooth loss and gingival recession.

Öz

Amaç: Bu retrospektif çalışmanın amacı, cerrahi destekli hızlı üst çene genişletmesi (CDHÜG) sonrasında maksiller dişlerin alveolar kemik yüksekliğindeki ve bukkal kemik kalınlığındaki (BKK) değişiklikleri konik ışınli bilgisayarlı tomografi (KİBT) kullanarak değerlendirmektir.

Gereç ve Yöntemler: Operasyon öncesi ve operasyon sonrası KİBT kayıtları olan toplam 9 hasta çalışmaya dahil edildi. Bütün hastalara CDHÜG yapıldı ve tamamına üst çene genişletici olarak modifiye akrilik bonded apareyi uygulandı. KİBT görüntüleri, CDHÜG öncesi (T1) ve 3-4 aylık bir konsolidasyon süreci sonrası (T2) alındı. Alveolar kemik yüksekliği, KİBT görüntülerinde mine-sement hududu ile alveolar kret tepesi arasındaki mesafenin ölçülmesiyle tespit edildi. BKK'yi değerlendirmek için kök yüzeyi boyunca iki farklı nokta tespit edildi.

Bulgular: T1 ve T2 alveolar kemik yüksekliği ölçümleri arasındaki farkla tespit edilen alveolar kemik kaybı (AKK) tüm dişlerin tüm yüzeylerinde istatistiksel olarak anlamlıydı. T1 ve T2 ölçümleri arasında her dişin her yüzeyinde BKK'de istatistiksel bir azalma vardı.

Sonuç: Modifiye akrilik bonded apareylerle yapılan CDHÜG, diş kaybı ve dişeti çekilmesi riskini artıran AKK'ye ve BKK'de bir azalmaya neden olur.

Introduction

Similar to rapid maxillary expansion (RME), surgically assisted rapid maxillary expansion (SARME) is a treatment for correcting transverse maxillary discrepancies and provides dental arch space for the alignment of the maxillary teeth. The main goal of RME is opening the skeletal sutures of the maxilla rather than moving the maxillary teeth out of the alveolar bone (1). However, sometimes maxillary teeth could be buccally tipped and dislocated from the position in the bone envelope as an undesired effect of this therapy (2). In adults, because of the sutural maturation, pain with activation of the expander, periodontal destruction and extrusion of the teeth, dental tipping, and alveolar bone bending rather than skeletal movement are some kinds of possible complications without surgical intervention (3). Therefore, SARME is performed in patients with complete skeletal maturity and closed cranial sutures (4).

There are various effects of orthodontic therapy on periodontium by plaque retention, direct traumatization of appliances and excessive and unfavorable forces (5). Fixed orthodontic appliances increase the retention of dental plaque which is the primary etiological factor of gingival inflammation and periodontal diseases (6). Alveolar bone loss (ABL) and decreased buccal bone thickness (BBT), which are some of the complications of maxillary expansion procedures with tooth-borne appliances (7), not only cause a reduction in periodontal support but also may result in mucogingival problems such as gingival recession.

The aim of this retrospective study was to evaluate the effects of SARME on ABL and BBT at the maxillary teeth using a modified acrylic bonded appliance by means of cone-beam computed tomography (CBCT).

Materials and Methods

The CBCT records of 9 subjects (5 males, 4 females) mean age of 19.67 ± 4 years were obtained from the archives of Necmettin Erbakan University Faculty of Dentistry. This study was approved by The Ethical Committee of Necmettin Erbakan University, Faculty of Dentistry with number 2020/02 (date: 13.02.2020) and was conducted in accordance with the Helsinki Declaration of 1975, as revised in 2000. An informed

consent form was obtained from all patients to go under CBCT scanning and to use their data in this study.

All patients had undergone SARME with a modified acrylic bonded device which was formed by a splint type tooth-tissue-borne appliance and a Hyrax screw in the center as a part of their orthodontic treatment (Figure 1). The acrylic part of the appliance extended over the occlusal and middle third of the vestibular surfaces of all the maxillary teeth (8). The appliance was cemented with a glass ionomer material that had been cleaned from the surfaces of the maxillary teeth after appliance removal at the end of the consolidation phase. T1 scans were obtained just before SARME, and T2 scans were taken after a consolidation period of 3 to 4 months. A CBCT device (3D Accuitomo 170 CBCT device, Morita, Tokyo, Japan) was used at 85.0 kV, 4.0 mA, and the scanning time was 17.5 seconds. Analysis of the radiographs was performed on a single monitor at 0.5 mm slice thickness using computer software (One Volume Viewer v.1.6.0.20, Morita, Tokyo, Japan).

Alveolar Bone Loss Assessments

All the maxillary teeth were examined except the third molars. Alveolar bone height (ABH) was measured as the distance from cemento-enamel junction (CEJ) to the alveolar crest (AC) using CBCT. For the purpose of further analyzing ABH, the distance from CEJ to AC was measured at the midpoint of the four sites of each tooth (buccal, palatal, mesial, distal). ABL was determined as the difference between T1 and T2 ABH measurements.

Buccal Bone Thickness Assessments

BBT was evaluated considering a previous study (9). Root length was determined as the distance from the horizontal reference line which was made at the radiographic level of CEJ to the root apex. Two points



Figure 1. The modified acrylic bonded maxillary expansion appliance which has occlusal coverage of all the maxillary teeth

were chosen to measure the width of the buccal bone. One of the measurement points (M1) was at the distance of 4 mm apical to the radiographic level of CEJ and the other measurement point (M2) was the midpoint of the root length. If the buccal bone was present but too thin to measure, then BBT was determined as 0.1 mm (Figure 2).

Statistical Analysis

In the comparison of the mean values of ABH and BBT between T1 and T2 CBCT measurements, the Wilcoxon signed-rank test and, a paired t-test were used for normally and non-normally distributed

data, respectively. We duplicated ABH measurements at four sites (buccal, palatal, mesial, distal) within 1 month in the maxillary right canine of all patients on T1 CBCT images to calculate the standard deviation and to establish intra-examiner reliability. The differences between the duplicated measurements were statistically compared with the paired t-test. All statistical analyses were conducted using software (SigmaPlot 12.5, Systat Software, San Jose, USA) and corrected p values are presented.

Results

ABL between T1 and T2 measurements were statistically significant at four sites (buccal, palatal, mesial, distal) of each measured tooth. Comparisons of the T1 and T2 measurements in terms of ABL of maxillary anterior and posterior teeth are shown in Table 1 and Table 2, respectively. There was a statistically significant decrease in BBT at each measured point (M1 and M2) of all the maxillary teeth. Comparisons of the T1 and T2 measurements in terms of BBT is shown in Table 3.

A negative correlation was detected between BBT before SARME and ABL at buccal site which wasn't statistically significant ($p=0.269$).

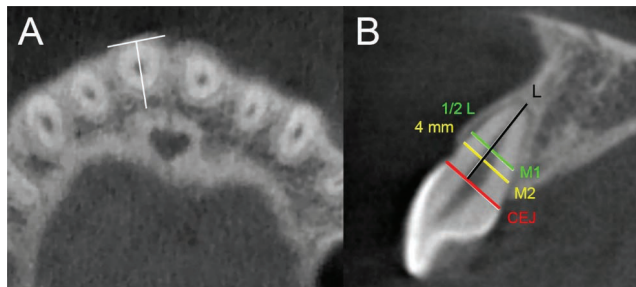


Figure 2. Buccal bone thickness A) The vertical angulation of the sagittal slice was set according to the long axis of the measured tooth. B) Measurements taken at M1 and M2 points CEJ=cemento-enamel junction, M1=4 mm apical to cemento-enamel junction, M2=1/2 length of the root, L=length of the root

Table 1. Distance from CEJ to AC of maxillary anterior teeth before and after SARME

Teeth	Region	Right segment			Left segment		
		T1*	T2*	p	T1*	T2*	p
Central incisor	Buccal	1.74±0.55	3.39±2.49	0.004	1.87±0.79	4.42±3.53	0.004
	Palatal	1.42±0.65	2.55±0.95	0.015	1.62±1.05	1.93±0.90	0.042
	Mesial	1.57±0.34	2.12±0.54	0.003	1.62±0.47	2.45±0.90	0.005
	Distal	1.50±0.45	2.07±0.58	<0.001	1.61±0.55	2.50±0.66	<0.001
Lateral incisor	Buccal	1.95±0.82	3.84±2.29	0.004	2.09±0.62	3.53±2.17	0.004
	Palatal	1.47±0.56	2.40±0.99	0.002	1.58±0.74	2.90±2.70	0.004
	Mesial	1.64±0.73	2.11±0.88	0.022	1.72±0.48	2.16±0.67	0.004
	Distal	1.76±0.67	2.32±1.03	0.024	1.64±0.41	2.34±0.83	0.005
Canine	Buccal	2.03±0.53	5.89±4.21	0.004	2.31±1.10	5.13±3.84	0.004
	Palatal	1.79±0.93	2.99±1.30	0.005	1.52±0.80	3.04±1.94	0.036
	Mesial	1.55±0.46	2.03±0.82	0.020	1.35±0.25	1.96±0.56	0.004
	Distal	1.54±0.66	2.07±0.72	0.003	1.27±0.35	1.85±0.46	<0.001

*Values are presented as mean ± standard deviation and as millimeters. $P<0.05$: Statistically significant difference compared to the baseline. CEJ: Cemento-enamel junction, AC: Alveolar crest, SARME: Surgically assisted rapid maxillary expansion

Table 2. Distance from CEJ to AC of maxillary posterior teeth before and after SARME

Teeth	Region	Right segment			Left segment		
		T1*	T2*	p	T1*	T2*	p
1 st Premolar	Buccal	1.92±0.70	4.75±3.25	0.004	2.36±0.84	5.30±3.24	0.024
	Palatal	2.14±0.71	4.04±2.52	0.004	2.24±1.21	3.62±1.49	0.004
	Mesial	1.59±0.43	1.88±0.47	0.002	1.52±0.54	2.14±0.78	<0.001
	Distal	1.55±0.57	1.92±0.51	0.003	1.60±0.48	1.93±0.65	0.004
2 nd Premolar	Buccal	1.96±0.79	2.83±0.87	0.002	1.78±0.64	2.56±1.22	0.009
	Palatal	1.99±0.69	3.08±1.01	0.002	1.85±0.76	2.86±1.09	0.003
	Mesial	1.60±0.51	2.12±0.54	0.010	1.51±0.52	1.91±0.65	0.007
	Distal	1.61±0.48	1.84±0.49	0.005	1.70±0.58	2.02±0.67	0.002
1 st Molar	Buccal	1.52±0.50	3.25±2.61	0.004	1.59±0.45	2.99±2.64	0.004
	Palatal	1.76±0.75	3.33±1.97	0.004	1.99±0.65	3.34±2.04	0.004
	Mesial	1.65±0.46	2.09±0.56	0.008	1.69±0.57	1.98±0.57	0.003
	Distal	1.78±0.69	2.08±0.75	0.003	1.61±0.74	2.14±1.01	0.004
2 nd Molar	Buccal	1.12±0.30	1.91±0.56	0.003	1.34±0.41	1.99±0.60	<0.001
	Palatal	1.51±0.49	2.84±1.13	0.006	1.82±0.74	2.63±0.98	0.004
	Mesial	1.79±0.59	2.16±0.83	0.011	1.45±0.52	1.99±0.65	0.006
	Distal	1.98±0.41	2.25±0.40	0.007	1.88±0.52	2.39±0.72	0.010

*Values are presented as mean ± standard deviation and as millimeters. P<0.05: Statistically significant difference compared to the baseline. CEJ: Cemento-enamel junction, AC: Alveolar crest, SARME: Surgically assisted rapid maxillary expansion

Table 3. BBT measurements at M1 and M2 points before and after SARME

Region	Right segment			Left segment		
	T1*	T2*	p	T1*	T2*	p
Central M1	0.85±0.23	0.49±0.38	0.005	0.86±0.12	0.39±0.40	0.006
Central M2	0.86±0.26	0.55±0.23	<0.001	0.87±0.25	0.49±0.38	0.003
Lateral M1	0.89±0.29	0.60±0.42	0.004	0.78±0.29	0.51±0.43	0.014
Lateral M2	0.84±0.41	0.70±0.38	0.007	0.81±0.48	0.66±0.44	0.016
Canine M1	0.69±0.31	0.14±0.21	0.004	0.79±0.45	0.24±0.31	0.012
Canine M2	0.58±0.23	0.22±0.29	<0.001	0.65±0.34	0.25±0.29	<0.001
1 st Premolar M1	0.88±0.46	0.51±0.47	0.008	1.04±0.28	0.33±0.57	0.002
1 st Premolar M2	0.71±0.46	0.29±0.31	0.014	0.69±0.49	0.19±0.31	0.010
2 nd Premolar M1	1.39±0.71	0.68±0.44	0.011	1.59±0.75	0.95±0.67	0.004
2 nd Premolar M2	1.47±0.76	0.69±0.63	<0.001	1.63±0.63	1.00±0.64	0.004
1 st Molar M1	1.47±0.57	0.95±0.48	0.006	1.46±0.52	0.94±0.50	0.008
1 st Molar M2	1.13±0.55	0.75±0.52	0.005	1.39±0.62	0.57±0.45	0.007
2 nd Molar M1	2.22±0.71	1.62±0.60	0.004	2.18±0.72	1.56±0.59	0.003
2 nd Molar M2	2.39±0.84	1.83±0.91	0.004	2.17±1.09	1.48±0.74	0.015

*Values are presented as mean ± standard deviation and as millimeters. P<0.05: Statistically significant difference compared to the baseline. BBT: Buccal bone thickness, SARME: Surgically assisted rapid maxillary expansion

There wasn't a statistically significant difference between the duplicated measurements to establish intra-examiner reliability ($p=0.275$).

Discussion

In this study, a modified acrylic bonded maxillary expansion appliance that had occlusal coverage of all the maxillary teeth was used. This tooth-tissue-borne appliance has been used to control vertical dimensional changes, and to reduce dental tipping and bite opening (10). Much earlier, another type of occlusal bonded RME device was compared with the banded appliances, and some advantages were reported in minimizing the downward and forward displacement of the maxilla (11). Besides these benefits for orthodontic treatment, it would not be wrong to think that patients cannot provide oral hygiene to all of their maxillary teeth during the whole treatment and retention period. In a current study investigating a bonded Haas type palatal expander with acrylic parts, the fixed orthodontic devices were thought as a clinical risk for enamel unity, as well as a risk factor for periodontitis (12). In another research on the subject, it was reported that except for the effect on the amount of dental plaque, fixed orthodontic appliances harbor the periodontal pathogens like *Aggregatibacter actinomycetemcomitans* with a remarkable frequency of detection in the bacterial plaque (13).

There is no consensus on the type of expansion device used in RME and SARME such as tooth-borne, tooth-tissue-borne, bone-borne, tooth-bone-borne (hybrid). Among these, bone-borne appliances seem to be more advantageous due to the lack of a direct relationship to the periodontium. However, the need for an extra surgical procedure, the presence of a secondary wound surface, the high cost, and the necessity of removal by the second surgical procedure are the reasons shown when not preferred (14). In a systematic study that evaluated CBCT studies on RME, some advantages of bone-borne to tooth-borne devices were declared in terms of reduced dental tipping (15). In a recent CBCT study, Moon et al. (16) reported a greater decrease in ABH and BBT in tooth-bone-borne appliances compared with tissue-bone-borne expanders at maxillary first molars. Another recent CBCT study in which tooth-borne with Hyrax type and tooth-tissue-borne with

Haas type appliances were investigated, reported a significant decrease in BBT and buccal ABH in both types of appliances at anchored maxillary first molars (17). Furthermore, a current study using bone-borne appliances showed some complications with a limited percentage after SARME, such as the formation of gingival recession and change of probing depths normal to pathologic (18). Similar mild periodontal damage was reported by Verlinden et al. (19) using the bone-borne appliance, but the results of the study were limited with only central incisors.

The most common cause of ABL is the extension of inflammation with dental plaque from marginal gingiva into the supporting periodontal tissues (20). Similar to the intensive forces exerted by occlusal trauma, the forces exerted by orthodontic appliances on anchored teeth can aggravate ABL in the presence of inflammation. In a current study, in which the effects of SARME on periodontal tissues by means of clinical periodontal examinations and CBCT images were evaluated, the authors reported ABL at buccal sites of 6 teeth from a total of 10 teeth that they examined with a statistical significance (21). A recent review evaluating some of these CBCT studies reported a significant vertical loss of alveolar bone at anchored teeth following maxillary expansion with tooth-borne appliances, similar to the results of our study (7).

The orthodontic forces applied to anchored teeth in the buccal direction during the maxillary expansion procedure, move these teeth buccally in the bone envelope. While a decrease in BBT at anchored teeth after maxillary expansion procedures is an expected result, whether the remaining bone thickness will be sufficient to maintain periodontal health is an important consideration. In a very recent study, D'Silva et al. (9) reported a significant correlation between gingival recession and thin buccal bone (<1 mm). In addition, an experimental study evaluating the periodontal effects of orthodontic treatments showed that the risk of the gingival recession may be greater if orthodontic forces proceed to create bone dehiscence (22). In this context, Gauthier et al. (21) noticed a significant decrease in BBT at all examined teeth except right and left canines which weren't bonded after SARME using CBCT. With a similar result, Kayalar et al. (23) noticed that BBT of anchored first molars in both tooth-borne and hybrid groups were decreased when compared to pre-and post-treatment

values with a statistical significance. In this study, different from other previous studies, we measured BBT from two points instead of one along the root surface and we found significant decreases in BBT at all anchored maxillary teeth.

Conclusion

When all the current studies are evaluated together with the results of this study, the negative effects of SARME on the periodontium at different severities were observed. The appliance types could increase or decrease this negative effect but seems to be hard to eliminate. Appliances that are more hygienic and apply less force to remove the tooth from the bone envelope can increase success in preventing periodontal diseases.

Ethics

Ethics Committee Approval: This study was approved by The Ethical Committee of Necmettin Erbakan University, Faculty of Dentistry with number 2020/02 (date: 13.02.2020) and was conducted in accordance with the Helsinki Declaration of 1975, as revised in 2000.

Informed Consent: An informed consent form was obtained from all patients to go under CBCT scanning and to use their data in this study.

Peer-review: Externally peer-reviewed.

Authorship Contributions

Surgical and Medical Practices: A.E., A.Y.G., D.M., A.E.S., Concept: Ç.E., Design: Ç.E., A.E., Data Collection or Processing: Ç.E., A.E., A.Y.G., D.M., A.E.S., Analysis or Interpretation: A.Y.G., Literature Search: Ç.E., Writing: Ç.E., A.E.

Conflict of Interest: No conflict of interest was declared by the authors.

Financial Disclosure: The authors declared that this study received no financial support.

References

- Pangrazio-Kulbersh V, Jezdimir B, de Deus Haughey M, Kulbersh R, Wine P, Kaczynski R. CBCT assessment of alveolar buccal bone level after RME. *Angle Orthod* 2013; 83: 110-6.
- Akyalcin S, Schaefer JS, English JD, Stephens CR, Winkelmann S. A cone-beam computed tomography evaluation of buccal bone thickness following maxillary expansion. *Imaging Sci Dent* 2013; 43: 85-90.
- Sokucu O, Kosger HH, Bicakci AA, Babacan H. Stability in dental changes in RME and SARME: a 2-year follow-up. *Angle Orthod* 2009; 79: 207-13.
- Carvalho PHA, Moura LB, Trento GS, Holzinger D, Gabrielli MAC, Gabrielli MFR, et al. Surgically assisted rapid maxillary expansion: a systematic review of complications. *Int J Oral Maxillofac Surg* 2020; 49: 325-32.
- Hinrichs JE. The role of dental calculus and other predisposing factors. In: Newman MG, Takei H, Klokkevold PR, Carranza FA, editors. *Carranza's clinical periodontology* tenth edition. St. Louis: Saunders Elsevier, 2006: 170-92.
- van Gastel J, Quirynen M, Teughels W, Coucke W, Carels C. Longitudinal changes in microbiology and clinical periodontal variables after placement of fixed orthodontic appliances. *J Periodontol* 2008; 79: 2078-86.
- Lo Giudice A, Barbato E, Cosentino L, Ferraro CM, Leonardi R. Alveolar bone changes after rapid maxillary expansion with tooth-borne appliances: a systematic review. *Eur J Orthod* 2018; 40: 296-303.
- Ileri Z, Basciftci FA. Asymmetric rapid maxillary expansion in true unilateral crossbite malocclusion: a prospective controlled clinical study. *Angle Orthod* 2015; 85: 245-52.
- D'Silva E, Fraser D, Wang B, Barmak AB, Caton J, Tsigarida A. The association between gingival recession and buccal bone at maxillary anterior teeth. *J Periodontol* 2020; 91: 484-92.
- Basciftci FA, Karaman AI. Effects of a modified acrylic bonded rapid maxillary expansion appliance and vertical chin cap on dentofacial structures. *Angle Orthod* 2002; 72: 61-71.
- Sarver DM, Johnston MW. Skeletal changes in vertical and anterior displacement of the maxilla with bonded rapid palatal expansion appliances. *Am J Orthod Dentofacial Orthop* 1989; 95: 462-6.
- Bagatin CR, Andruccioli MCD, Ferreira JTL, Matsumoto MAN, da Silva RAB, da Silva LAB, et al. Biofilm formation in Haas palatal expanders with and without use of an antimicrobial agent: an in-situ study. *Microsc Res Tech* 2017; 80: 471-7.
- Paolantonio M, di Girolamo G, Pedrazzoli V, di Murro C, Picciani C, Catamo G, et al. Occurrence of *Actinobacillus actinomycetemcomitans* in patients wearing orthodontic appliances. A cross-sectional study. *J Clin Periodontol* 1996; 23: 112-8.
- Seeberger R, Abe-Nickler D, Hoffmann J, Kunzmann K, Zingler S. One-stage tooth-borne distraction versus two stage bone-borne distraction in surgically assisted maxillary expansion (SARME). *Oral Surg Oral Med Oral Pathol Oral Radiol* 2015; 120: 693-8.
- Krüsi M, Eliades T, Papageorgiou SN. Are there benefits from using bone-borne maxillary expansion instead of tooth-borne maxillary expansion? A systematic review with meta-analysis. *Prog Orthod* 2019; 20: 9.
- Moon HW, Kim MJ, Ahn HW, Kim SJ, Kim SH, Chung KR, et al. Molar inclination and surrounding alveolar bone change relative to the design of bone-borne maxillary expanders: A CBCT study. *Angle Orthod* 2020; 90: 13-22.
- Lemos Rinaldi MR, Azeredo F, Martinelli de Lima E, Deon Rizzato SM, Sameshima G, Macedo de Menezes L. Cone-beam computed tomography evaluation of bone plate and root length after maxillary expansion using tooth-borne and tooth-tissue-

- borne banded expanders. *Am J Orthod Dentofacial Orthop* 2018; 154: 504-16.
18. Ramieri GA, Spada MC, Austa M, Bianchi SD, Berrone S. Transverse maxillary distraction with a bone-anchored appliance: dento-periodontal effects and clinical and radiological results. *Int J Oral Maxillofac Surg* 2005; 34: 357-63.
 19. Verlinden CR, Gooris PG, Becking AG. Complications in transpalatal distraction osteogenesis: a retrospective clinical study. *J Oral Maxillofac Surg* 2011; 69: 899-905.
 20. Carranza FA, Takei HH. Bone loss and patterns of bone destruction. In: Newman MG, Takei H, Klokkevold PR, Carranza FA, editors. *Carranza's clinical periodontology* 10th edition. St. Louis: Saunders Elsevier, 2006: 452-66.
 21. Gauthier C, Voyer R, Paquette M, Rompré P, Papadakis A. Periodontal effects of surgically assisted rapid palatal expansion evaluated clinically and with cone-beam computerized tomography: 6-month preliminary results. *Am J Orthod Dentofacial Orthop* 2011; 139: 117-28.
 22. Wennström JL, Lindhe J, Sinclair F, Thilander B. Some periodontal tissue reactions to orthodontic tooth movement in monkeys. *J Clin Periodontol* 1987; 14: 121-9.
 23. Kayalar E, Schauseil M, Kuvat SV, Emekli U, Fıratlı S. Comparison of tooth-borne and hybrid devices in surgically assisted rapid maxillary expansion: A randomized clinical cone-beam computed tomography study. *J Craniomaxillofac Surg* 2016; 44: 285-93.