

Journal of Pediatric Sciences

Epidural haematoma by Mayfield head-holder®: Case report and review of literature

Jacopo C. Poli, Cesare Zoia, Desiree Lattanzi, Sergio Balbi

Journal of Pediatric Sciences 2013;5:e195

How to cite this article:

Poli JC, Zoia C, Lattanzi D, Balbi S. Epidural haematoma by Mayfield head-holder®: Case report and review of literature. Journal of Pediatric Sciences. 2013;5:e195

CASE REPORT

Epidural haematoma by Mayfield head-holder®: Case report and review of literature

Jacopo C. Poli, Cesare Zoia, Desiree Lattanzi, Sergio Balbi

Department of Surgical Sciences, Neurosurgical Unit- University of Insubria Varese,
Azienda Ospedaliero-Universitaria Ospedale di Circolo e Fondazione Macchi, Varese (Italy)

Abstract:

A lot of neurosurgical interventions require the use of a pin-type head-holder to immobilize the patients' head. We report the case of an epidural haematoma caused by penetration of head holders' pin in a 7-year-old boy. The haematoma was showed by a head CT-scan at the end of surgery performed to treat a cerebellar astrocytoma that was managed surgically. Mmany factors seem to contribute to elevate the risk of complications due to the use of the Mayfield head-holder. Prevention and management measures are discussed also through a review of literature.

Keywords: *Mayfield skull clamp - Depressed skull fracture - Epidural haematoma - Cerebellar astrocytoma*

Corresponding author: *Jacopo C. Poli; Via Cremona 47, 21020 Taino; Varese- Italy*

Telephone number: 00393333167569

Fax number: 00390332278948

E-mail: j.poli@hotmail.it

Introduction

The Mayfield (Ohio Medical Instrument Co., Cincinnati, OH, USA) skull clamp®, a modification of the Gardner headholder [10], is worldwide used in neurosurgical practice. Its function is to fix and hold, thanks to its three pins, the patient's head during surgical interventions. Only few complications, caused by the use of this -or other types of pins head-holder- have been reported in literature. [2,4,6-8,11,15-18,20-22,25,26,28]. The risk of adverse events is greater in the paediatric population probably due to the thickness of the developing cranium [5,27]. We report a case of a 7 year-old boy, in whom the use of the Mayfield skull clamp® produced a skull fracture and an epidural hematoma, and we review literature on this subject.

Case report

A 7 year-old boy presented with a history of headache, vomiting, loss of concentration and reduction in school performance. A computed tomography (CT) scan and a nuclear magnetic resonance (NMR) revealed a posterior fossa cystic tumour with an enhancing mural nodule in the left cerebellar hemisphere. The lesion was approached with a left suboccipital craniectomy with the patient placed in prone position. The head was fixed in a Mayfield three-point skull clamp® with paediatric pins and a 50 lbs force was applied. The tumour was gross-totally removed and the histopathological examination confirmed the diagnosis of a pylocytic astrocytoma, previously suggested by frozen section examination. At the end of the procedure the patient presented left anisocoria; a post-

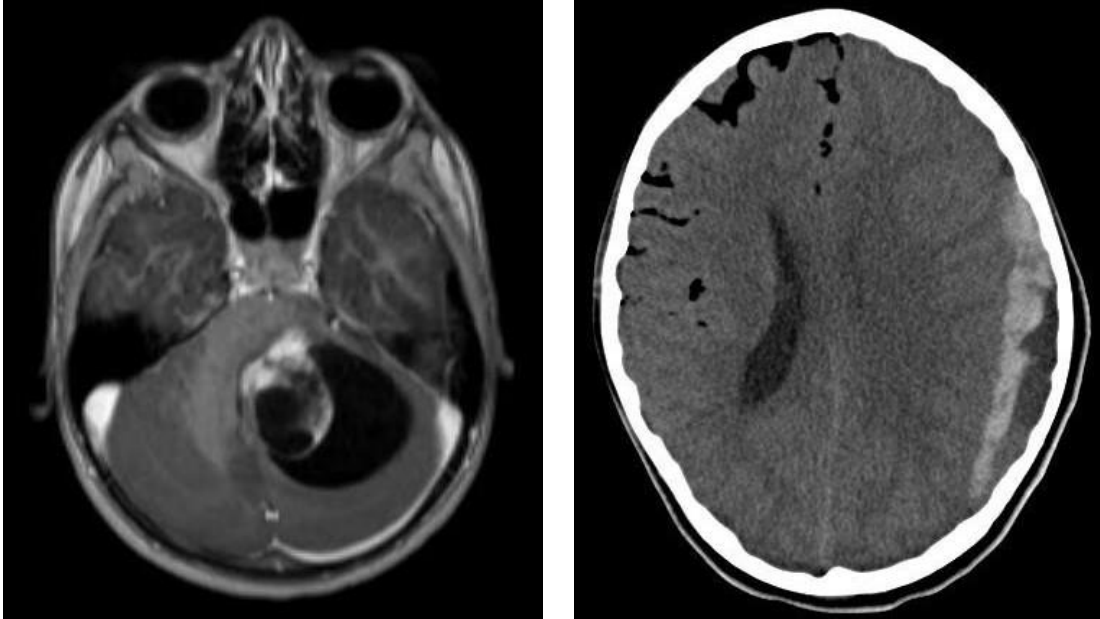


Figure 1 and 2. Post-operative CT-scan imaging showing a left hemispheric epidural haematoma with a small depressed skull fracture at the site of the single pin.

operative CT-scan revealed a left hemispheric epidural haematoma with a small depressed skull fracture at the site of the single pin [figure 1 and 2].

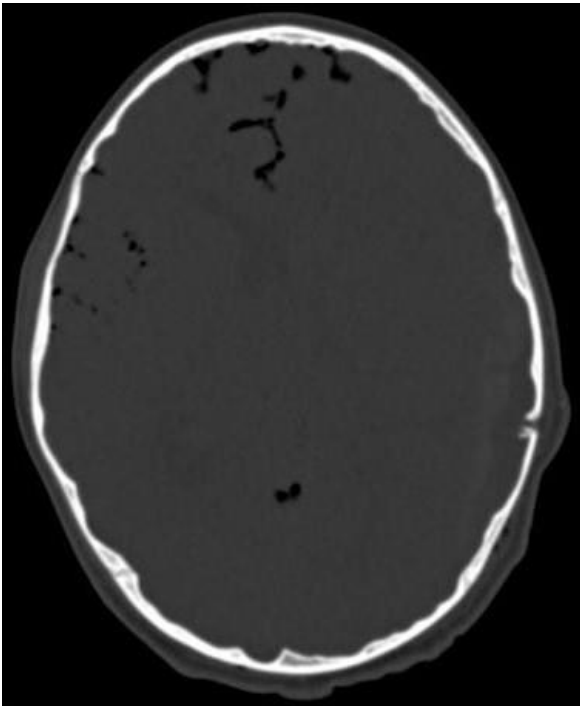


Figure 3. Post-operative CT-scan imaging showing complete epidural haematoma evacuation.

The patient underwent immediately surgical evacuation of the haematoma by a wide fronto-temporo-parietal craniotomy. The post-operative CT-scan showed the complete removal of the haematoma [figure 3], and a later brain MR excluded any residual of the tumour. The patient was discharged to be sent home thirteen days after surgical intervention without neurological deficit.

Discussion

The Mayfield (Ohio Medical Instrument Co., Cincinnati, OH, USA) skull clamp® is probably the most used head holder in neurosurgical intracranial and cervical spine interventions, when it is mandatory to stabilise and hold the patient's head. Pin head holders (in general) are generally considered very safe devices and only few complications are reported in literature. Adverse events are reported both in paediatric [2,4,15,17,21,25,28] and adult [6,11,16,18,20,22] populations, but the risk of complications due to head holder is higher in paediatric patients. The thickness of the developing cranium is maybe the most important cause of skull fractures by head holders pins [5,27]. In addition, excessive

pin pressure, a long standing raised intracranial pressure and long-lasting surgical interventions could increase the risk of this complication [17]. For these reasons special care should be taken in positioning of pins headholders when treating paediatric population.

The most reported complications of this device are epidural haematoma [4,7,8,16,20,22,25,28], venous air embolism [6,11,21,26] and depressed skull fractures [15,17,18]; other possible complications are cerebrospinal fluid leak, subdural haematoma, scalp lacerations, damage to shunt system, tension pneumocephalus, bleeding from pin sites, infection at pin sites, head slippage, pseudoaneurysm of the superficial temporal artery, traumatic middle meningeal arteriovenous fistula and breakage of the head rest [2,5,9,13,14,18,25].

To avoid these events, especially in the paediatric population, several alternative fixation systems or modifications of the pins headholders were proposed and discussed in the past [1,3,12,19,23]. However, pins head holders, and particularly the Mayfield skull clamp®, remain the most worldwide used head fixation systems, also in the paediatric population [5]. Wong and Haynes have demonstrated that there is no safe area for pins positioning in the paediatric skull [27]. Berry et al. tried to find out some guidelines for the use of cranial fixation pins in paediatric neurosurgical patients, and they suggested specific ranges of pressure in relation to the age of the patient [5]. We can say that for most of the authors, if the patient is older than 10, he is treated like an adult as far as the use of pins headholders is concerned [5]. Considering also the Mayfield skull clamp® instruction manual, Integra LifeScience Corporation states that skull pins are not recommended for use in children under five years of age and Mayfield Child skull pins® are recommended for young children over the age of five. In our department we try to avoid the use of headholders in children under the age of five and we use it only when necessary in the paediatric population older than five with a pressure lower than 50 lbs.

The Mayfield skull clamp® is probably the most frequently used head-holder in neurosurgical procedures. Only few complications are reported in literature both in the paediatric and in the adult populations. Physicians must be aware of these complications, especially in paediatric population, because the risk is higher with this kind of patients, and avoid the use of headholders when not strictly necessary.

Disclaimer

The authors report no conflict of interest concerning the materials or methods used in this study or the findings specified in this paper.

References

1. Agrawal D, Steinbok P: Simple technique of head fixation for image-guided neurosurgery in infants. *Childs Nerv Syst.* 22(11):1473-4, 2006
2. Anegawa S, Shigemori M, Yoshida M, Kojo N, Torigoe R, Shirouzu T, Kuramoto S: Postoperative tension pneumocephalus--report of 3 cases. *No Shinkei Geka.* 14(8):1017-22, 1986 [Article in Japanese]
3. Aoki N, Sakai T. Modified application of three-point skull clamp for infants. *Neurosurgery.* 25(4):660-2, 1989
4. Baerts WD, de Lange JJ, Booij LH, Broere G: Complications of the Mayfield skull clamp. *Anesthesiology* 61(4):460-1, 1984
5. Berry C, Sandberg DI, Hoh DJ, Krieger MD, McComb JG: Use of cranial fixation pins in pediatric neurosurgery. *Neurosurgery* 62(4):913-8; discussion 918-9, 2008.
6. Cabezudo JM, Gilsanz F, Vaquero J, Areitio E, Martinez R: Air embolism from wounds from a pin-type head-holder as a complication of posterior fossa surgery in the sitting position. *Case report. J Neurosurg.* Jul;55(1):147-8, 1981
7. Chi-Tun-Tang, Cheng-Ta Hseigh, Yung-Hsiao Chiang Yih-Huei-Sui: Epidural hematoma and depressed skull fracture resulted from pin head rest: *Case report. Cesk Slov neurol N* 103:584-6, 2007

8. Erbayraktar S, Gokmen N, Acar U: Intracranial penetrating injury associated with an intraoperative epidural haematoma caused by a spring-laden pin of a multipose headrest. *Br J neurosurg* 15:425-8, 2001
9. Fernández-Portales I, Cabezudo JM, Lorenzana L, Gómez L, Porras L, Rodríguez JA. Traumatic aneurysm of the superficial temporal artery as a complication of pin-type head-holder device. Case report. *Surg Neurol* 52:400-403, 1999
10. Gardner W J: Intracranial operations in the sitting position. *Ann Surg* 101:138-146, 1993
11. Grinberg F, Slaughter TF, McGrath BJ: Probable venous air embolism associated with removal of the Mayfield skull clamp. *Anesth Analg.* 80(5):1049-50, 1995
12. Gupta N: A modification of the Mayfield horseshoe headrest allowing pin fixation and cranial immobilization in infants and young children. *Neurosurgery.* 58(1 Suppl):ONS-E181; discussion ONS-E181, 2006
13. Heifetz MD. Use and misuse of instruments in Apuzzo MLJ (Ed): *Brain surgery : complications avoidance and management.* New York: Churchill Livingstone, pp71-90, 1993
14. Inagawa T, Takeda T, Taguchi H, Kamiya K, Yamada T. Traumatic middle meningeal arteriovenous fistula caused by three-point skull fixation. Case report. *J Neurosurg* 60:853-855, 1984
15. Lee M, Rezai AR, Chou J : Depressed skull fractures in children secondary to skull clamp fixation devices. *Pediatr Neurosurg.* 21(3):174-7; discussion 178, 1994
16. Lee MJ, Lin EL: The use of the three-pronged Mayfield head clamp resulting in an intracranial epidural hematoma in an adult patient. *Eur Spine J.* 19 Suppl 2:S187-9, 2010
17. Martínez-Lage JF, Almagro MJ, Serrano C, Mena L: Depressed skull fracture by a three-pin head holder: a case illustration. *Childs Nerv Syst.* 27(1):163-5, 2011
18. Matouk CC, Ellis MJ, Kalia SK, Ginsberg HJ: Skull fracture secondary to application of a Mayfield skull clamp in an adult patient: Case report and review of the literature. *Clin Neurol Neurosurg.* 2012
19. Muzumdar DP, Bhatjiwale MG, Goel A: Plaster of Paris mould for stereotactic frame fixation. *Pediatr Neurosurg.* 41(5):229-32, 2005
20. Naik V, Goyal N, Agrawal D: Pin site bilateral epidural hematoma - a rare complication of using Mayfield clamp in neurosurgery. *Neurol India.* 59(4):649-51, 2011
21. Pang D: Air embolism associated with wounds from a pin-type head-holder. Case report. *J Neurosurg.* 57(5):710-3, 1982
22. Sade B, Mohr G: Depressed skull fracture and epidural haematoma: an unusual post-operative complication of headrest in adult. *Acta Neurochir (Wien)* 147:101-3, 2005
23. Sgouros S, Grainger MC, McCallin S: Adaptation of skull clamp for use in image-guided surgery of children in the first 2 years of life. *Childs Nerv Syst.* 21(2):148-9, 2005
24. Taira T, Tanikawa T. Breakage of Mayfield head rest. *J Neurosurg* 77:160-161, 1992
25. Vitali AM, Steinbok P: Depressed skull fracture and epidural hematoma from head fixation with pins for craniotomy in children. *Childs Nerv Syst.* 24(8):917-23; discussion 925, 2008
26. Wilkins RH, Albin MS: An unusual entrance site of venous air embolism during operations in the sitting position. *Surg Neurol.* 7(2):71-2, 1977
27. Wong WB, Haynes RJ: Osteology of the pediatric skull. Considerations of halo pin placement. *Spine (Phila Pa 1976).* 1;19(13):1451-4, 1994
28. Yan HJ: Epidural hematoma following use of a three-point skull clamp. *J Clin Neurosci.* 14(7):691-3, 2007