

Chiari-like malformation in a cat

Mehmet Nur ÇETİN^{1,a,✉}, Batuhan NEYSE^{2,b}, Yusuf Sinan ŞİRİN^{1,c}, Büşra Nur KILIÇ YILDIZ^{2,d}

¹Mehmet Akif Ersoy University Department of Surgery, Burdur, Türkiye; ²Mehmet Akif Ersoy University Institute of Health Sciences Burdur, Türkiye

^aORCID: 0000-0003-2610-8477; ^bORCID: 0000-0001-6862-482X; ^cORCID: 0000-0003-1322-7290; ^dORCID: 0000-0003-2166-0959

ARTICLE INFO

Article History

Received : 10.10.2023

Accepted : 22.02.2024

DOI: 10.33988/auvfd.1373633

Keywords

Chiari-like malformation

Cat

Neuropathic pain

Syringomyelia

✉Corresponding author

mncetin@mehmetakif.edu.tr

How to cite this article: Çetin MN, Neyse B, Şirin YS, Kılıç Yıldız BN (2025): Chiari-like malformation in a cat. Ankara Univ Vet Fak Derg, 72 (1), 117-120. DOI: 10.33988/auvfd.1373633.

ABSTRACT

Chiari-like malformations are rare in cats. In this case report, the aim is to share data on the diagnosis and treatment of a Chiari-like malformation in a cat. This case report is for an 8-month-old, 3 kg, female, mixed-breed cat. The cat was brought in by its owner with complaints of seizures and weakness in the hind limb. Clinical and neurological examination revealed signs of ataxic gait, tetraparesis, allodynia, and decreased corneal reflexes. As a result of the examinations, a cranial or cervical lesion was suspected. Magnetic resonance imaging revealed findings such as ventriculomegaly, cerebellar herniation, medullary kinking, syringomyelia, and decreased cerebrospinal fluid flow at the first cervical level. Computed tomography revealed the absence of atlantooccipital overlap. In light of the findings, the patient was diagnosed with a Chiari-like malformation. Phenobarbital, gabapentin, furosemide, and prednisone were used for medical treatment. However, despite a week of medical treatment, no improvement was observed. Foramen magnum decompression was preferred as the operation method and titanium mesh was used to prevent scar tissue formation. The patient, whose condition improved in the postoperative period, died one week later due to aspiration pneumonia.

Chiari-like malformation (CM) is a complex malformation that results in crowding of the caudal fossa and displacement of the cerebellum toward the foramen magnum. The resulting overcrowding of the craniocervical junction causes abnormal cerebrospinal fluid (CSF) dynamics, leading to the formation of syringomyelia (SM) (fluid spaces within the spinal cord) (3). CM and SM are common conditions in small and toy-breed dogs, such as the Cavalier King Charles Spaniel (CKCS) (1).

The most common clinical signs of CM/SM are neuropathic pain, yelping, vocalization on sudden posture change, scratching with or without skin contact, scoliosis, ataxia, and weakness (10, 11). The diagnosis of CM and SM is based on history, clinical signs (neurological signs) and diagnostic imaging (5, 8). Magnetic resonance imaging (MRI) is the gold standard diagnostic tool to assess CM and SM (15). Computed tomography (CT) can be used to confirm or exclude cerebellar herniation and is used as a diagnostic tool when MRI is not available (5, 8).

There are two treatment approaches, medical and surgical, for CM and SM (5).

Although most frequently described in dogs, CM has rarely been described in cats. There are two reports of suspected CM in cats, two in domestic shorthair cats with imaging findings consistent with CM (7), and two in Persian cats (4).

In this study, we tried to include data on the diagnosis and treatment of CM, which is rare in cats.

The material in this case is an 8-month-old mixed-breed cat, weighing 3 kg, brought to the University of Burdur Mehmet Akif Ersoy, Faculty of Veterinary Medicine. The patient presented complaints of weakness in the hind limb and seizures. There was evidence of ear discharge in the clinical examination. A swab was taken from the ear, but no pathological factor could be isolated. Neurological examination revealed tetraparesis, pain when trying to turn (generalized pain), and decreased corneal reflex. The complete blood count and serum chemistry profile were within the normal ranges for all

parameters. The serologically evaluated feline immunodeficiency virus, feline leukemia virus tests, and toxoplasma and feline infectious peritonitis tests were negative. As a result of the tests, a cranial or cervical lesion was suspected. No findings were obtained on cranial and cervical radiographs. Magnetic resonance imaging of the brain and cervical spine and CT were performed on admission under general anesthesia using a 1.5 T magnetic resonance imaging helical CT scanner with the patient in the prone position. Sedation was provided with xylazine (1 mg/kg intramuscular (IM)) and induction with ketamine (15 mg/kg, IM). T2-weighted sequences (TR: 3800, TE: 100) and HASTE sequences (TR: 8000, TE: 346) were obtained on MRI. On T2-weighted imaging, there was caudal cerebellar herniation, medulla oblongata, syringomyelia beginning from cervical 2 (C2) and extending to the beginning of the thoracic spine, and ventriculomegaly in the lateral ventricles. In the HASTE sequence, the accumulation of CSF starting from the C2 region and extending to the thoracic region is seen as hyperintense. The CSF level decreases at the foramen magnum and cervical 1 (C1) spine levels. (Figure 1). On CT scans, the sagittal plane (WL: 800, WW: 2000, ST:

0.14 mm) and the transverse plane (WL: 60, WW: 300, ST: 1 mm) were taken. The original CT data were transferred as DICOM images (Digital Imaging and Communications in Medicine) to an image analysis workstation to perform image analysis. SM has frequently been associated with CM and, more recently, with atlantooccipital overlap (AOO); however, SM can occur as a single malformation or as part of several craniocervical malformations in the same patient (6). On sagittal CT, a line (McRae line) (14) was drawn from the cranial to the caudal of the occipital bone and it was evaluated whether there was an AOO. Since the line did not cut any part of the atlas arc, it was understood that there was no AOO (Figure 2).

Based on these data, the patient was diagnosed with CM. First, the patient received medical treatment. Phenobarbital (2 mg/kg, per oral (PO), q 12 h) for seizures and gabapentin (2.5 mg/kg PO, q 12 h) for neuropathic pain; furosemide (2 mg/kg IV, q 12 h) as a diuretic; and prednisone (0.5 mg/kg, q 24 h) were administered as medical treatment. However, despite treatment, no improvement was observed, so surgery was decided.

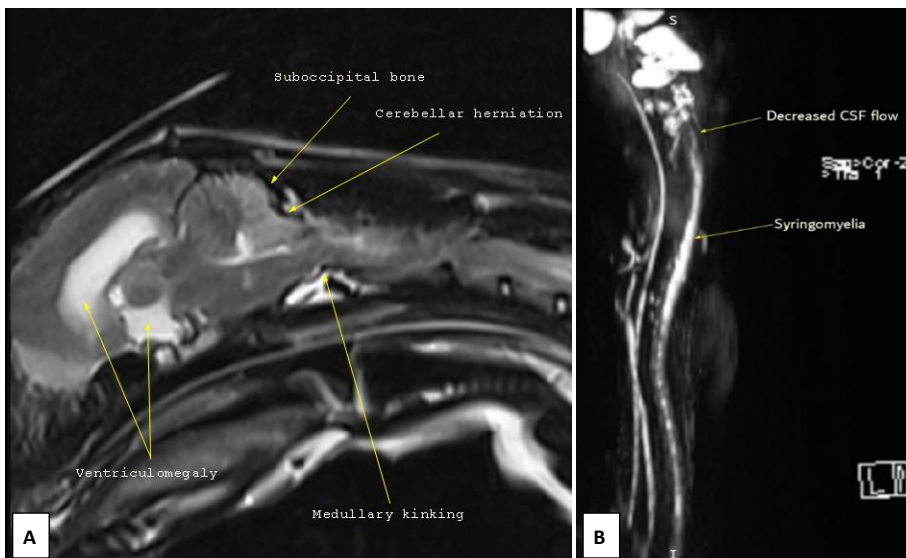


Figure 1. Chiari malformation findings on T2-weighted sagittal imaging (A), HASTE sequence showing syringomyelia (B).

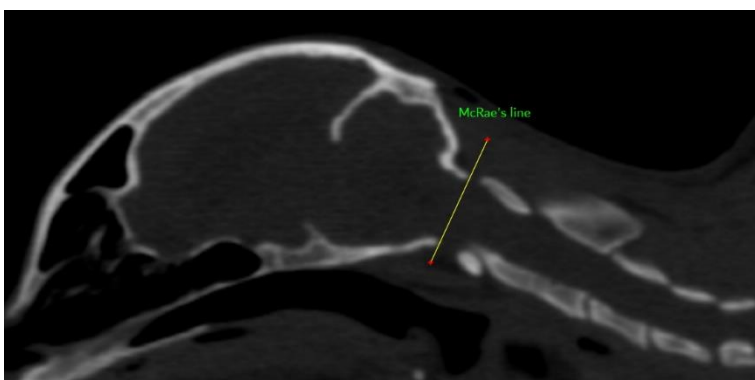


Figure 2. McRae's line drawn for the evaluation of AOO.

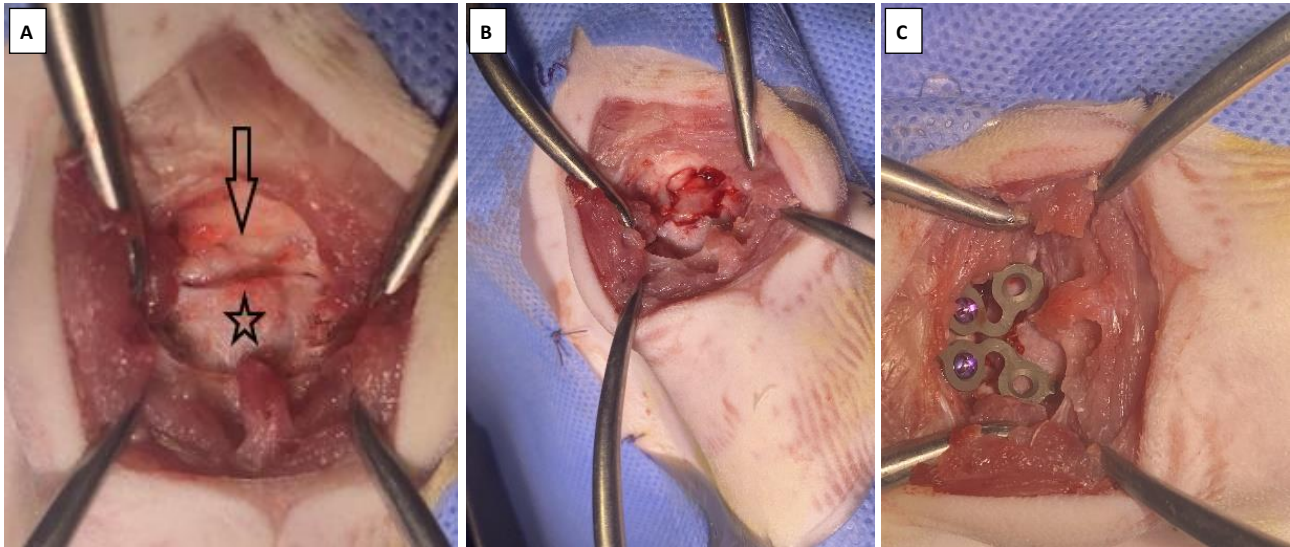


Figure 3. Intraoperative view of the suboccipital bone (arrow) and the arcus atlantis (star) (A), decompressed supoccipital bone and arcus atlantis (B), application of titanium mesh (C).

Foramen magnum decompression was preferred as the surgical method. Cefazolin (22 mg/kg, intravenous (IV)) was used half an hour before the operation for premedication, and butorphanol (0.1 mg/kg, IV) was used for analgesia. Diazepam (0.2 mg/kg, IV) was used for premedication in anesthesia, and propofol (6 mg/kg, IV) was used for induction and maintenance with sevoflurane. The patient was placed in dorsoventral recumbency. A roller was placed under the patient's neck in a way that did not increase the venous pressure, so that the patient's head remained flexed and the head was fixed. A caudal incision was made from the external occipital protuberance to the caudal border of the dorsal process spinosus of C2. The superficial cervical muscles were dissected and the musculus biventer cervicis muscle was exposed. The musculus biventer cervicis muscle was dissected along the median line and the separated musculus rectus capitis muscle was exposed. The cranial part of this muscle was dissected sharply from the crista nuchae, and the caudal part from the cranial part of C2. The suboccipital bone and the dorsal arch of the C1 were reached. Using a high-speed air drill, a window was opened by taking the nuchal crest border to the suboccipital bone and then 75% of the arcus atlantis of C1 was removed. The fibrous band in the cervicomedullary region was removed. Three holes were drilled around the suboccipital window for the placement of the titanium mesh. The head was returned to its normal position and the titanium mesh was shaped like a guitar pick to cover C1. Screws with a length of 4 mm and a diameter of 1.5 mm were inserted into these holes with a depth of 2–3 mm. PMMA was prepared and applied in such a way that it slightly overflowed the titanium mesh. The muscle layers and the deep layers were then closed routinely (Figure 3). The patient was awakened from

general anesthesia and placed in a soft-filled cage. Tramadol hydrochloride (1 mg/kg, subcutaneous (SC), q 12 h) was used postoperatively for analgesia. Postoperative cefazolin (22 mg/kg, IV, q 8 h) was used as antibiotic therapy. However, the patient's condition began to improve in the postoperative period, but a week later, the patient died of aspiration pneumonia.

Kroff and Williamson (4) reported that two cats had similar clinical signs, including difficulty prehending food, head and cranial-cervical junction pain on palpation, extended head and neck posture, and behavioral changes like aggression, restlessness, grooming, and polyphagia. In the case report of Mitano and Baroni (7), both cats showed clinical signs of ataxia. In the present case report, clinical findings such as ataxic gait, seizure, tetraparesis, mild touch pain, and decreased corneal reflex were present.

It has been reported that the occurrence of SM varies according to age, with 45% in dogs one year old and younger, 40% in dogs aged 1–4 years, and 15% in dogs aged five and over (10). SM was not observed in either case report on cats (4, 7). In one case report, both cats were 2 years old (7), while in the other case report, one cat was 10 years old and the other 5 years old (4). In the presented case, it was thought that SM was more likely to occur at younger ages, which is consistent with dogs, since the cat was 8 months old and had SM. In the other two case reports presented, cats did not have SM and were older.

The SM, or syrinx, which is generally associated with the central canal, can affect the dorsal horn, resulting in abnormal processing of sensory information that causes neuropathic pain (2). The cause of neuropathic pain was thought to be advanced SM that extends from the cervical region to the thoracic region.

Neuropathic pain most often manifests as allodynia (pain arising from a non-noxious stimulus, i.e., gentle palpation) (9), or dysaesthesia (a spontaneous or evoked unpleasant sensation that manifests as phantom scratching or facial or ear rubbing) (12). The resulting pain was thought to be neuropathic pain and this pain manifested as allodynia.

The diagnosis of CM in CKCS is made by caudal cerebellar herniation, kinking in the caudal medulla oblongata, and the absence of the CSF signal at the level of the occluded foramen magnum on MRI (sagittal and transverse T2-weighted sequences) (13). All the magnetic resonance findings in the presented case were consistent with all the magnetic resonance findings for CM in CKCS.

Surgical management of CM and SM is generally reserved for patients that have not responded well to conservative management (3). The most common surgical procedure for the management of SM is cranial/cervical decompression. The aim is to allow the flow of CSF by removing the supraoccipital bone at the back of the skull and part of the top of the first vertebrae. It is possible to overcome this through surgical cranioplasty and the use of a titanium mesh to prevent the development of postoperative scar tissue (16). As the case did not respond to medical treatment, foramen magnum decompression was preferred as a surgical procedure. Titanium mesh was used to prevent the formation of postoperative scar tissue.

Financial Support

This research received no grant from any funding agency/sector.

Ethical Statement

This study does not present any ethical concerns.

Conflict of Interest

The authors declared that there is no conflict of interest.

Author Contributions

MNÇ and YŞŞ conceived and planned the experiments. MNÇ and YŞŞ carried out the experiments. MNÇ, YŞŞ, BN and BY contributed to the interpretation of the results. MNÇ took the lead in writing the manuscript. All authors provided critical feedback and helped shape the research, analysis and manuscript.

Data Availability Statement

The data supporting this study's findings are available from the corresponding author upon reasonable request.

Animal Welfare

The authors confirm that they have adhered to ARRIVE Guidelines to protect animals used for scientific purposes.

References

1. **Couturier J, Rault D, Cauzinille L** (2008): *Chiari-like malformation and syringomyelia in normal cavalier King Charles spaniels: a multiple diagnostic imaging approach*. J Small Anim Pract, **49**, 438-443.
2. **Freeman AC, Platt SR, Kent M, et al** (2014): *Chiari-Like Malformation and Syringomyelia in American Brussels Griffon Dogs*. J Vet Intern Med, **28**, 1551-1559.
3. **Hechler AC, Moore SA** (2018): *Understanding and Treating Chiari-like Malformation and Syringomyelia in Dogs*. Top Companion Anim Med, **33**, 1-11.
4. **Korff CP, Williamson BG** (2020): *Clinical presentation of Chiari-like malformation in two Persian cats*. Top Companion Anim Med, 100460.
5. **Kromhout K, van Bree H, Broeckx BJG, et al** (2014): *Low-Field MRI and Multislice CT for the Detection of Cerebellar (Foramen Magnum) Herniation in Cavalier King Charles Spaniels*. J Vet Intern Med, **29**, 238-242.
6. **Loughin CA** (2016): *Chiari-like Malformation*. J Small Anim Pract, **46**, 231-242.
7. **Minato S, Baroni M**, (2017): *Chiari-like malformation in two cats*. J Small Anim Pract, **59**, 578-582.
8. **Peih-Yik CM, Zoe S, Okene IA** (2020): *Chiari-Like Malformation and Syringomyelia in a Cavalier King Charles Spaniel*. Intern Med J, **27**, 144-147.
9. **Plessas IN, Volk HA, Rusbridge C, et al** (2015): *Comparison of gabapentin versus topiramate on clinically affected dogs with Chiari-like malformation and syringomyelia*. Vet Rec, **177**, 288.
10. **Rusbridge C** (2013): *Chiari-like malformation and syringomyelia*. Europe Journ Comp Anim Pratic, **23**, 70-89.
11. **Rusbridge C, Carruthers H, Dube MP, et al** (2007): *Syringomyelia in Cavalier King Charles spaniels: the relationship between syrinx dimensions and pain*. J Small Anim Pract, **48**, 432-436.
12. **Rusbridge C, Jeffery ND** (2008): *Pathophysiology and treatment of neuropathic pain associated with syringomyelia*. Vet Journal, **175**, 164-172.
13. **Rusbridge C, Knowler SP** (2003): *Hereditary aspects of occipital bone hypoplasia and syringomyelia (Chiari type I malformation) in cavalier King Charles spaniels*. Vet Rec, **153**, 107-112.
14. **Waschk M, Vidondo B, Carrera I, et al** (2019): *Craniovertebral Junction Anomalies in Small Breed Dogs with Atlantoaxial Instability: A Multicentre Case-Control Study*. Veterinary and Comparative Orthopaedics and Traumatology. Vet Comp Orthop Traumatol, **32**, 33-40.
15. **Weber SM, Hostnik ET, Drost WT, et al** (2020): *Comparison of high-field MRI and multidetector CT for grading Chiari-like malformation and syringomyelia in Cavalier King Charles Spaniels*. Vet Radiol Ultrasound, 1-9.
16. **Wolfe K, Poma R** (2010): *Syringomyelia in the Cavalier King Charles spaniel (CKCS) dog*. CVJ, **51**, 95-102.

Publisher's Note

All claims expressed in this article are solely those of the authors and do not necessarily represent those of their affiliated organizations, or those of the publisher, the editors and the reviewers. Any product that may be evaluated in this article, or claim that may be made by its manufacturer, is not guaranteed or endorsed by the publisher.