

## Siirt-Colored Mohair Goat (*Capra Hircus*) and Romanov Sheep (*Ovis Aries*) Determination of Morphometric Features of Hyoid Bone via Three Dimensional Modelling

Muhammed Zahid ATLI<sup>1,a,✉</sup>, Fatma İŞBİLİR<sup>1,b</sup>, Barış Can GÜZEL<sup>1,c</sup>

<sup>1</sup>Department of Anatomy, Faculty of Veterinary Medicine, Siirt University, Siirt, TÜRKİYE.

ORCID: <sup>a</sup>0009-0007-3139-1453, <sup>b</sup>0000-0002-6110-1302, <sup>c</sup>0000-0002-2504-120X

### ✉ Corresponding Author

Muhammed Zahid ATLI

Department of Anatomy, Faculty of  
Veterinary Medicine, Siirt University,  
Siirt, TÜRKİYE

mzahid.atli@siirt.edu.tr

Received  
20.09.2024

Accepted  
20.03.2025

Published  
30.06.2025

DOI  
10.47027/duvetfd.1553193

**How to cite:** Atli MZ, İşbilir F, Güzel BC (2025). Siirt-Colored mohair goat (*Capra Hircus*) and romanov sheep (*Ovis Aries*) determination of morphometric features of hyoid bone via three dimensional modelling. *Dicle Univ Vet Fak Derg.*, 18(1):19-22.

This journal is licensed under a Creative Commons Attribution-Non Commercial 4.0 International License (CC BY-NC 4.0).



### Abstract

The hyoid bone is the only bone that connects caudally to the tympanohyoid and stylohyoid processes of the pars petrosa of the temporal bone and does not articulate with any other bone. The hyoid bone plays a crucial role in maintaining the balance and functionality of the respiratory tract, as well as in language functions and swallowing. Morphometric studies on the hyoid bone have been conducted in both humans and animals. With advancements in technology, two-dimensional (2D) structures have been replaced by three-dimensional (3D) modeling. Our study is the first to determine the morphometric properties of the hyoid bone in sheep and goats using the 3D modeling method. For this purpose, 40 hyoid bone models from adult Siirt-colored mohair goats (10 females, 10 males) and Romanov sheep (10 females, 10 males) were utilized. All 40 bones were modeled, and measurements were obtained from the models. Skull sections were taken with a computed tomography device and recorded in DICOM format. The images were transferred to the 3D-Slicer (5.2) software program and 3D models were made. Five morphometric parameters were measured simultaneously for two animal species from these models. Measurement results were evaluated statistically between male and female animals. The correlation between measurement parameters was determined by correlation analysis. As a result of the study, the stylohyal length (SL) measurement parameter had a statistical difference between genders in both sheep and goats. Additionally, it was determined that the epihyal length (EL) value showed a significant difference between male and female goats in Siirt-colored mohair goats. When the correlation analysis table was examined, it was determined that the SL parameter had a positive correlation with CL and TL, and the TL parameter had a positive correlation with CL and BL in the two animal species. We believe that the differences in the hyoid bone of these two races, which are in the Ruminantia subgroup and have different phenotypes, will contribute to the literature. In addition, the data will serve as a reference for relevant studies in the fields of veterinary medicine, anatomy education, surgery, pathology, and zoo-archaeology.

**Key Words:** Hyoid bone, morphometry, romanov sheep, siirt-colored mohair goats, 3D modelling

### Siirt Renkli Tiftik Keçisi (*Capra hircus*) ve Romanov Koyunu (*Ovis aries*) Dil Kemisinin Morfometrik Özelliklerinin 3D Modelleme Aracılığıyla Belirlenmesi

#### Öz

Hiyoid kemik, kaudal olarak temporal kemiğin pars petrosa bölümündeki timpanohiyoid ve stilohiyoid çıkıntılarına bağlanan ve başka hiçbir kemikle eklem yapmayan tek kemiktir. Hiyoid kemik, solunum yolunun dengesi ve işlevselliğinin korunmasının yanı sıra dil fonksiyonları ve yutma işlemlerinde de hayati bir rol oynar. Hiyoid kemiği üzerine morfometrik çalışmalar hem insanlarda hem de hayvanlarda gerçekleştirilmiştir. Teknolojideki ilerlemelerle birlikte, iki boyutlu (2B) yapılar yerini üç boyutlu (3B) modellemeye bırakmıştır. Çalışmamız, koyun ve keçilerde hiyoid kemiğin morfometrik özelliklerini 3B modelleme yöntemiyle belirleyen ilk araştırmadır. Bu amaçla, yetişkin Siirt renkli tiftik keçisi (10 dişi, 10 erkek) ve Romanov koyunu (10 dişi, 10 erkek) olmak üzere toplam 40 hiyoid kemik modeli kullanılmıştır. Tüm kemikler 3B olarak modellenmiş ve bu modeller üzerinden ölçümler gerçekleştirilmiştir. Kafatası kesitleri, bilgisayarlı tomografi cihazı ile alınarak DICOM formatında kaydedilmiş ve görüntüler 3D-Slicer (5.2) yazılımına aktarılarak 3B modeller oluşturulmuştur. Her iki hayvan türü için bu modellerden beş morfometrik parametre eş zamanlı olarak ölçülmüştür. Ölçüm sonuçları, erkek ve dişi hayvanlar arasında istatistiksel olarak değerlendirilmiştir. Ölçüm parametreleri arasındaki ilişki ise korelasyon analizi ile belirlenmiştir. Çalışmanın sonucunda, stilohiyal uzunluğu (SL) ölçüm parametresinin hem koyun hem de keçilerde cinsiyetler arasında istatistiksel olarak farklılık gösterdiği belirlenmiştir. Ayrıca, epihyal uzunluğu (EL) değerinin, Siirt renkli tiftik keçilerinde erkek ve dişi bireyler arasında anlamlı bir farklılık gösterdiği tespit edilmiştir. Korelasyon analizi tablosu incelendiğinde, SL parametresinin CL ve TL ile pozitif korelasyon gösterdiği, TL parametresinin ise CL ve BL ile pozitif korelasyon gösterdiği belirlenmiştir. Ruminantia alt grubunda yer alan ve farklı fenotiplere sahip bu iki ırkın hiyoid kemiğindeki farklılıkların literatüre katkı sağlayacağına inanıyoruz. Ayrıca, elde edilen veriler veteriner hekimlik, anatomi eğitimi, cerrahi, patoloji ve zoo-arkoloji alanlarındaki ilgili çalışmalara referans oluşturacaktır.

**Anahtar Kelimeler:** Dil kemiği, morfometri, romanov koyunu, siirt renkli tiftik keçisi, 3D modelleme

## INTRODUCTION

The majority of colored mohair goats in Turkey are raised in the provinces of Siirt, Batman, and Şırnak. Romanov sheep are another breed grown in the Eastern Anatolia Region, and the purpose of breeding these two breeds in this region is to know that these animals have important characteristics (1). The Romanov sheep is known for its high fertility and characteristic hairy skin features. It is characterized by a short head, legs, and tail structure, as well as a black-gray body color (2,3). The Siirt-colored mohair goat is a breed particularly used for mohair production in the region. The mohair obtained from these goats is used in the production of Siirt blankets, which are popular as tourist souvenirs. Male goats have longer horns, and their ears are more drooping compared to female goats. Their coats are generally black, white, brown, yellow, and red (4). Morphometric differences observed on the skull have been frequently used in recent years for breed and gender differentiation. The usability of the hyoid bone alone in such differentiation remains a topic of interest.

The hyoid bone exhibits different articulation characteristics depending on the animal species. In cats and dogs, it connects to the processus mastoideus of the os temporale, while in equines and ruminants, it attaches to the processus styloideus of the os temporale. Additionally, in pigs, the hyoid bone articulates with the region of the os occipitale known as the processus jugularis (5).

Hyoid bone plays an important role in the balance and adequacy of the respiratory tract, language function, and swallowing (6). In addition, this bone structure has an important role in the clinic. One study found differences in the position of the hyoid bone in jaw dysplasia (7). Os hyoideum is related to swallowing and tongue physiology, therefore any disorder in this structure will negatively affect functions such as swallowing (8). The morphology of this bone varies according to age and gender, so it can also be used in age and gender determinations. Sex differences in the hyoid bone were identified through radiographic measurements and morphometric analyses. Males showed significantly larger dimensions compared to females, including the width and breadth of the body, as well as the length and breadth of the greater cornu. The anterior and posterior ends of the greater cornu were also significantly wider in males. These differences are likely associated with the generally larger skeletal and muscular structure in males (9).

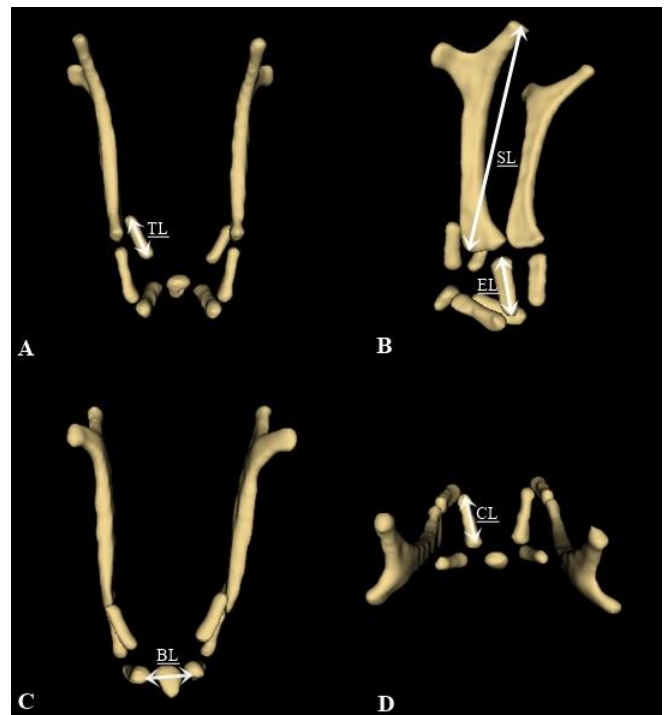
In anatomy education, which has an important place in medicine and veterinary medicine, practical education is more important than theoretical, therefore the use of 3D modeling is increasing significantly. The biggest advantage of 3D modeling in anatomy education is that the material preserves its structure and shape (10). 3D modeling allows multiple production of dissected material at any size scale to produce anatomically accurate reproductions (11). One of the significant advantages of modeling is making deformed or more fragile bone specimens more durable (10). With the 3D modeling of the hyoid bone, its use as an educational material for different animal species is expected to increase. There are 3D morphometric studies of different animal species in the literature (12-14). Detailed description of the

morphological characteristics of Siirt-colored mohair goats is unclear due to insufficient research.

This study aims to obtain morphometric measurement values by three-dimensional modeling of the hyoid bone in Siirt-colored mohair goats and Romanov sheep using computerized tomography and to reveal the biometric differences of these measurement values according to gender and other breeds. In addition, the data obtained will serve as a resource for anatomy literature and taxonomy.

## MATERIAL AND METHODS

In our study, 40 hyoid bone models of adults (1-3 years old); Siirt-colored mohair goats (10 females and 10 males) and Romanov sheep (10 females and 10 males) were used. No clinical findings were observed in the skulls used in the study. The materials used in the study were collected from slaughterhouses in Siirt and Diyarbakır province. The measurement parameters of the hyoid bone are shown in Figure 1. Skulls of sheep and goats were scanned at Siirt University Faculty of Medicine Hospital, Department of Radiology, with a 64-detector multi-slice computed tomography device at 80 kV, 200 MA, 639 mGY, with a section thickness of 0.625 mm. The resulting images were saved in DICOM format. The images were then transferred to 3D-Slicer (5.2) software programs to create three-dimensional models. IBM SPSS Statistics 23 package program was used for statistical measurements. Independent Samples t test was used to compare measurements between genders. Pearson correlation analysis was used to reveal the correlation between measurements.



**Figure 1.** A. Cranial view of the Romanov sheep, B. Lateral view of the Romanov sheep, C. Caudal view of the Mohair goat, D. Dorsal view of the Mohair goat

Morphometric measurement points of hyoid bone of Romanov sheep and Siirt-colored mohair goat. SL: Stylohyal lenght, EL: Epihyal lenght, CL: Ceratohyal lenght, TL: Tyhrohyal lenght, BL: Basihyal lenght

## RESULTS

In our study, the independent Samples t test and correlation analysis results of the hyoid bones of the Siirt-colored mohair goat and the Romanov sheep are shown in Tables 1, 2, and 3. SL and EL parameters were found to be statistically significant between sexes in Siirt-colored mohair goats ( $P<0.01$ ). It was determined that other measurement parameters did not have a statistically meaningful difference ( $P>0.05$ ). In Romanov sheep, the SL measurement parameter had a statistically significant difference between male and female animals ( $P<0.05$ ). No statistically significant difference was determined in other measurement parameters ( $P>0.05$ ). When the correlation analysis table was examined, it was determined that the SL parameter had a positive correlation with CL and TL, and the TL parameter had a positive correlation with CL and BL in the two animal species.

**Table 1.** Statistical analysis of hyoid bone of Siirt-colored mohair goat (Independent Samples t test)

	Gender	N	Mean	Std. Deviation	P
SL	Male	10	65.22	1.80	0.009*
	Female	10	61.64	0.85	
EL	Male	10	15.84	1.07	0.002*
	Female	10	13.48	0.45	
CL	Male	10	15.76	0.67	0.473
	Female	10	13.42	0.56	
BL	Male	10	9.88	0.44	0.605
	Female	10	8.52	0.40	
TL	Male	10	20.47	0.63	0.126
	Female	10	18.14	0.37	

\* :  $P<0.01$

**Table 2.** Statistical analysis of Romanov sheep hyoid bone (Independent Samples t test)

	Gender	N	Mean	Std. Deviation	P
SL	Male	10	63.22	1.99	0.022*
	Female	10	59.63	0.74	
EL	Male	10	13.84	1.07	0.163
	Female	10	12.77	3.45	
CL	Male	10	13.74	0.68	0.229
	Female	10	12.02	1.14	
BL	Male	10	7.62	1.60	0.183
	Female	10	6.52	0.40	
TL	Male	10	18.47	0.63	0.368
	Female	10	16.06	0.46	

\* :  $P<0.05$

**Table 3.** Correlation analysis of hyoid bone of Siirt-colored mohair goat and Romanov sheep (n:40)

	SL	EL	CL	BL	TL
SL	1				
EL	0.296	1			
CL	0.861(**)	0.403	1		
BL	0.561	0.367	0.656(*)	1	
TL	0.895(**)	0.517	0.894(**)	0.730(*)	1

## DISCUSSION AND CONCLUSION

Due to its high fertility, the Romanov sheep breed is a widely bred breed in the world. Due to the disadvantages of 2D examinations in the anatomical definition of a structure, 3D modeling has gained importance (15,16). Our study is the first to include 3D modeling of the hyoid bone in sheep and goats.

Morphometric studies on hyoid bone in sheep and goat breeds are quite limited in the literature (13). In a study (17), on fetal development of sheep the morphometry of the hyoid bone was measured between the 12th and 20th weeks. In the study, the SL parameters were determined to be  $12\pm0.408$  mm and  $26.375\pm0.239$  mm at the 12th and 20th weeks, respectively. In a study conducted in humans (18), the average left hyoid length in males and females was found to be  $39.54\pm5.13$  mm and right hyoid length was  $39.25\pm5.02$  mm. Right and left SL lengths were measured as  $25.61\pm4.53$  mm and  $25.44\pm4.50$  mm, respectively, in males. The same parameter was reported in females as  $24.79\pm4.11$  mm and  $24.79\pm4.11$  mm on the right and left sides. In our study, the SL parameter was determined as  $65.22\pm1.80$  mm in male goats and  $61.64\pm0.85$  mm in female goats. A statistically significant difference was found between male and female goats in terms of SL value ( $P<0.01$ ). Likewise, in the Romanov sheep breed, the same parameter showed a statistically significant difference between genders ( $P<0.05$ ).

Rasouli and Yousefi (19) determined the radiological features of the skull in the Indian gray mongoose and aimed to define it macroscopically by making morphometric measurements of the hyoid bone. As a result of the study, CL and EL parameters were reported to be approximately 4-6 mm. In the 20 week old sheep fetus, CL and EL parameters were reported as  $7\pm0.0$  mm and  $4.875\pm0.125$  mm, respectively. Significant differences have been detected in the total lengths of the bones forming the hyoid apparatus between the 12th and 20th weeks of fetal development ( $P<0.05$ ). The length of the stylohyoid bone has been found to be significantly different from all other hyoid bones ( $P<0.05$ ). Additionally, the lingual process has shown a significant difference in length compared to the other bones ( $P<0.05$ ). A statistically significant difference has also been observed between the lengths of the thyrohyoid and keratohyoid bones ( $P<0.05$ ) (17). In our study, no difference was found between genders in terms of these two parameters in Romanov breed sheep. However, in Siirt-colored Mohair goats, while the CL parameter did not differ between genders, a statistical difference was detected in terms of the EL parameter. The EL parameter had a higher value in male goats than in female goats.

TL and basihyal length (BL) measurement data in the Indian gray mongoose have been reported as 7-8 mm (19). In a study (20) examined the osseous development of the hyoid bone of the New Zealand white rabbit and performed morphometric measurements at this stage. In a 1-day-old rabbit, the TL length was measured as 1.9 mm, and on the 7th day, it was 2.8 mm. In the last period of the study,

It was determined to be 4.2 mm. In Period 2, the length and width of the Basihyoid bone were reported as 2.2 mm and 2.5 mm, respectively. In our study, it was determined that TL and BL parameters did not show a statistical difference in male and female animals. However, the TL parameter had a positive correlation with SL and CL. Additionally, as

a result of the correlation analysis performed in the study, a positive correlation was determined between CL and SL measurement values. Statistically significant differences have been found in the ossification processes among all age groups ( $P<0.05$ ).

In conclusion, the determined parameters were measured by making 3D modeling of the hyoid bone from the images obtained by computer tomography in Siirt colored mohair goat and Romanov sheep breeds. In addition to sex differences within the same species, two different species were also compared. It is thought that this study will contribute to relevant studies in the fields of veterinary medicine, anatomy, pathology, zoo-archaeology, and surgery.

## FINANCIAL SUPPORT

No support was received from any organization in the conduct of this research.

## CONFLICT OF INTEREST

There is no conflict of interest to be declared by the authors.

## CONTRIBUTIONS

The concept of the study was determined by MZA, Fİ, and BCG. The design of the study was created by BCG and Fİ. The study was supervised by MZA and Fİ. The resources were provided by MZA and BCG. The materials for the study were supplied by BCG, MZA, and Fİ. Data collection and/or processing were performed by MZA and Fİ. The analysis and/or interpretation of the study was carried out by BCG and Fİ. The literature review was conducted by MZA. The manuscript was written by MZA and Fİ. The critical review was performed by Fİ and MZA.

## ETHICAL STATEMENT

With the ethics committee report numbered 2023/01/05 and 2023/01/03, the Siirt University Experimental Animals Application and Research Center approved the procedures used in our investigation.

## REFERENCES

- Şen M, Uğurlu M (2021). Romanov koyun ırkında dölverimi özellikleri, yaşama gücü, büyüme performansı ve bazı vücut ölçüleri. *Atatürk Üniv Vet Bilim Derg.*, 16(2):155-163.
- Akcapınar, H (2000). Koyun Yetiştiriciliği, II. baskı, İsmat Matbaacılık, Ankara.
- Korkmaz MK, Emsen E (2018). Growth and reproductive traits of purebred and crossbred Romanov lambs in Eastern Anatolia. *Anim Reprod.*, 13(1):3-6.
- Yertürk M, Odabasıoğlu F (2007). Investigation on the yield characters of the colored mohair goats being bred in the eastern and southeastern parts of Anatolia. *Van Vet J.*, 18(2):45-50.
- König HE, Liebich HG (Ed), Türkmenoğlu İ (Çeviri Editörü) (2020). Veteriner Anatomi (Evcil Memeli Hayvanlar). 7. Baskı, Medipres, Malatya, Türkiye.
- Bolatlı G (2013). Multidedektör bilgisayarlı tomografi görüntülerinde os hyoideum morfolojisinin yaşa ve cinsiyete göre incelenmesi. Yüksek Lisans Tezi. Selçuk Üniversitesi Sağlık Bilimleri Enstitüsü, Konya.
- Jena AK, Duggal R (2011). Hyoid bone position in subjects with different vertical jaw dysplasias. *Angle Orthod.*, 81(1):81-85.
- Galvão C (2013). Hyoid bone's cephalometric positional study in normal occlusion and in malocclusion patients. *Rev Odontol UNESP.*, 12(1/2):143-152.
- Shimizu Y, Kanetaka H, Kim YH et al. (2005). Age-related morphological changes in the human hyoid bone. *Cells Tissues Organs*, 180(3):185-192.
- Bakıcı C, Akgün RO, Oto Ç (2019). The applicability and efficiency of 3 dimensional printing models of hyoid bone in comparative veterinary anatomy education. *Vet Hekim Der Derg.*, 90(2):71-75.
- McMenamin PG, Quayle MR, McHenry CR, Adams JW (2014). The production of anatomical teaching resources using three-dimensional (3D) printing technology. *Anat Sci Educ.*, 7(6):479-486.
- Baygeldi SB, Güzel BC, Kanmaz YA, Yılmaz S (2022). Evaluation of skull and mandible morphometric measurements and three-dimensional modelling of computed tomographic images of porcupine (*Hystrix cristata*). *Anat Histol Embryol.*, 51(4):549-556.
- Dayan MO, Demircioğlu İ, Koçyiğit A, Güzel BC, Karaavcı FA (2023). Morphometric analysis of the skull of Hamdani sheep via three-dimensional modelling. *Anat Histol Embryol.*, 52(2):215-222.
- İşbilir F, Güzel BC (2023). Morphometric analysis of the mandible of ram and ewe romanov sheep (*Ovis aries*) with 3D modelling: A CT study. *Anat Histol Embryol.*, 52(5):742-751.
- Vernon T, Peckham D (2002). The benefits of 3D modelling and animation in medical teaching. *J Audiov Media Med.*, 25(4):142-148.
- Rubio RR, Di Bonaventura R, Kournoutas I et al. (2020). Stereoscropy in surgical neuroanatomy: Past, present, and future. *Oper Neurosurg.*, 18(2):105-117.
- Ahmed NS, Mahmood SK (2013). Bone development in hyoid apparatus of indigenous sheep. *Aust. J Basic Appl Sci.*, 7(10):547-552.
- Kopuz C, Ortug G (2016). Variable morphology of the hyoid bone in anatolian population: clinical implications-a cadaveric study. *Int J Morphol.*, 34(4):1396-1403.
- Rasouli B, Yousefi MH (2023). Skull, mandible and hyoid apparatus in the Indian grey mongoose (*Herpestes edwardsii*): A comprehensive anatomical study. *Anat Histol Embryol.*, 52(3):373-380.
- Atalgın H, Kürtül I, Bozkurt EU (2007). Postnatal osteological development of the hyoid bone in the new zealand white rabbit. *Vet Res Commun.*, 31:653-660.