

## CASE REPORT

# Removal of a Giant Dual Sialolith Located in Right Submandibular Gland Duct: A Case Report

Nuri Mert Tayşi <sup>1ROR</sup> and Aysegül Erten Tayşi <sup>1ROR</sup>, \*<sup>1</sup>Department of Oral and Maxillofacial Surgery, Istanbul University-Cerrahpaşa, Faculty of Dentistry, Istanbul, Türkiye

\*Corresponding Author; denterten@gmail.com

## Abstract

The prevalence of sialolithiasis in the salivary glands is reported to be 1%, with approximately 80% of cases occurring in the submandibular glands. Notably, sialolithiasis in these submandibular cases typically presents as a single solid formation. This paper aims to present a clinical case involving two sialoliths and review current treatments for sialolithiasis. A 51-year-old female patient was referred to the Istanbul University-Cerrahpaşa Faculty of Dentistry for evaluation due to swelling on the right side of the floor of the mouth. Her medical and dental history was unremarkable. The patient's physical status was classified as ASA-I, indicating she was healthy, non-smoking, did not consume alcohol, and had an appropriate BMI for her age. A cone beam computed tomography scan was requested following the assessment of orthopantomography and intraoral and extraoral physical examinations to confirm the presumptive diagnosis. The tomography revealed two sialoliths, which were surgically removed under local anesthesia via an intraoral approach. No functional sequelae were observed during the six-month postoperative follow-up period.

**Keywords:** Case report; Diagnostic imaging; Salivary Gland Calculus; Stomatognathic Diseases; Submandibular Glands

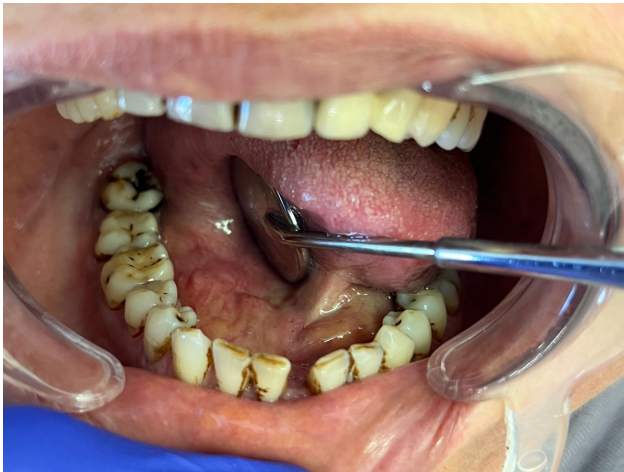## Introduction

Sialolithiasis is one of the most common salivary gland diseases, affecting 60 million people a year.<sup>1</sup> Sialolithiasis has an estimated prevalence rate ranging between 0.01% and 0.003% of the population worldwide.<sup>2,3</sup> The primary age of diagnosis is between 30 and 60 and the prevalence of occurrence is reported to be two men for every woman.<sup>4</sup> The exact etiology of sialolithiasis is unclear; however there are two main theories for identifying their pathophysiological mechanism.<sup>5</sup> While first theory depends on multiple internal microcalculi within salivary gland secretory granules acting as a nidus for the formation of larger calculi, the second theory postulates an inflammatory origin resulted in bacteria or food debris within oral cavity entering the distal region of salivary gland duct. In the second theory, this organic and foreign substrate serve as a nidus for the formation of larger calculi.<sup>5,6</sup>

The distribution of sialoliths shows a significant preference for the submandibular gland (approximately 85%), followed by the parotid gland (15%), with the sublingual and minor salivary glands accounting for less than 5% of the cases.<sup>7</sup> The higher incidence of sialolith formation in the submandibular gland is attributed to several anatomical and physiological factors. Anatomical factors include a longer Wharton's duct, larger duct caliber, and tortuous

course of the Wharton's duct accompanied by a slow salivary velocity. Physiological factors are related to the composition of saliva and mineral contents, such as calcium and phosphate levels.<sup>8</sup> Due to the submandibular gland's distinctive features, including mucinous saliva secretion and elevated levels of inorganic salts resulting in increased salivary alkalinity, there is a facilitation in the formation of sialolithiasis. Moreover, the slower salivary flow rate of the submandibular glands compared to other salivary glands is primarily attributed to the formation of a retrograde flow dynamic as the submandibular gland has two bends which is traveling upward and forward, and then its duct ascends against gravity toward its orifice in the oral cavity.<sup>8</sup> There are also some predisposing factors including tobacco consumption, insufficient fluid intake, and use of medications (e.g., diuretics, bendroflumethiazide) that reduce salivary output.<sup>3</sup> A retrospective study indicates that smoking and increased serum sodium concentrations correlate with larger sialolith formation.<sup>9</sup>

The analysis of sialolithiasis' laterality reveals that 75% of cases of sialolithiasis are unilateral, 3% are bilateral and 2% are atrophic.<sup>10</sup> In a cohort study, submandibular sialolithiasis demonstrated the following distribution pattern: right-sided involvement in 55% of cases, left-sided involvement in 42%, and bilateral presentation in 2%.<sup>3</sup> On the other hand, the pattern of sialolith formation is



**Figure 1.** Preoperative intraoral examination revealed a firm, palpable swelling in the right floor of the mouth along the Wharton's duct.

predominantly unilateral, with single stones being the most common presentation.<sup>11,12</sup> Previous studies<sup>12,13</sup> report that while single sialoliths comprise 75.3% of cases, multiple stone formations are less prevalent, with dual and triple sialoliths occurring in 15.6% and 2.9% of cases, respectively.

In this case report, we describe the surgical removal of two pieces of sialoliths arising from the right Wharton's duct with no functional sequelae observed during the six-month postoperative follow-up period.

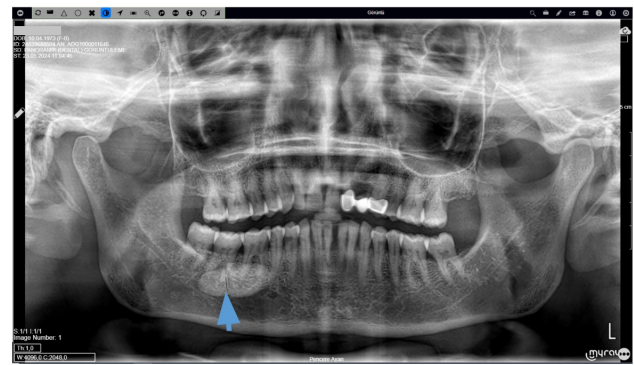
## Case Report

A 51-year-old female patient was referred to the oral and maxillo-facial surgery department by her general dentist due to persistent swelling in her lower right jaw. She reported a tender swelling under her tongue on the right side that had persisted for two years, which temporarily subsided with antibiotic treatment but did not fully resolve. The patient's medical history was unremarkable, and recent blood work and biochemical analysis were within normal limits. The patient is a non-smoker and has never consumed alcohol. At the time of examination, she did not have a fever but reported dysphagia and pain upon palpation.

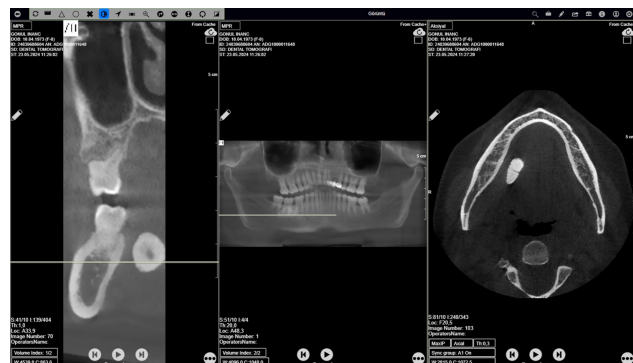The extraoral examination indicated swelling in the floor of the mandible extending toward the neck. Bilateral examination of the lymph nodes showed unilateral enlarged, non-tender, and mobile nodes on the right side. The patient's medical and dental history did not reveal any pathological clinical data relevant to the current condition.

Subsequent intraoral examination revealed a slightly visible swelling in the middle to the posterior part of the right side of the floor of the mouth (Figure 1). Throughout the bi-manual palpation of the area, there was a large, hard mass without any fluctuation. After the examination of the panoramic radiograph (Figure 2), a radiopaque appearance with a not precise radiolucent perpendicular dividing line was observed, and the solid mass was assumed to be related to a sialolithiasis of the submandibular gland in the initial assessment.

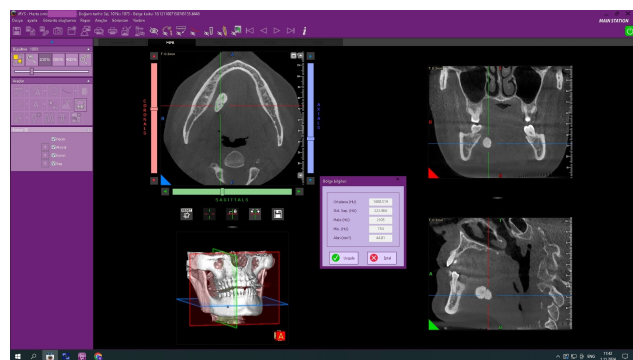
The patient was referred to the radiology department for CBCT (Cone Beam Computed Tomography) imaging for advanced radiological assessment prior to surgery. The CBCT (MyRay, Cefla Dental Group, Imola, Italy) volumetric data sets were reconstructed to display 2D images in 0.3 mm sections in three planes: axial, sagittal, and coronal, and viewed in their dedicated software (Figure 3). Images dedicated to two-pieces of sialolithiasis with a hyperdense area of approximately 1680.5 Hounsfield Units within the right sight of the mouth floor (Figure 4). The boundaries of sialolithiasis



**Figure 2.** The panoramic radiograph reveals a bipartite sialolith.



**Figure 3.** Cone-beam computed tomography present exact anatomical position of the sialolith for optimal surgical planning.

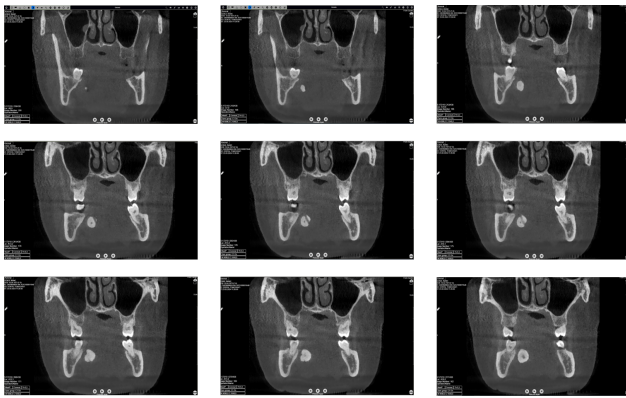


**Figure 4.** Hounsfield Units (HU) analysis demonstrates significant mineralization with a mean value of 1680.5 HU.

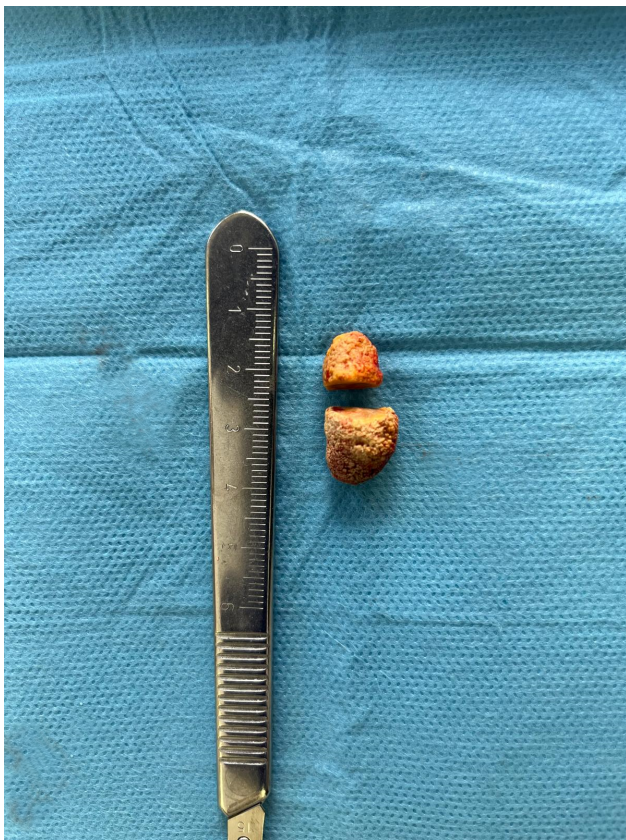was examined through several sections in a step-by-step manner (Figure 5) and commenced with the tooth number of 46 and extended to the wisdom tooth area. The hyperdense mass was found to be in the lingual side of the mandible without any contact to the bony structure. This finding confirmed that our initial diagnosis of sialolith was correct. According to the physical and radiological evaluations, removal of the sialolith was planned to be performed with an intraoral approach without removing the salivary gland.

Informed consent for the removal of sialolithiasis, which includes potential complications such as transient or permanent lingual nerve dysfunction, numbness, gustatory changes, seroma, hematoma, and recurrence, was obtained from the patient. Initially, the stone was located using the bimanual palpation method. The suspected area of the stone was then infiltrated with 2% lidocaine hydrochloride combined with 1:80,000 epinephrine (Lidofast, Vem Pharma Inc., and Trading Co. Ltd.). Following administration of local anesthesia, two sutures of 2.0 silk were placed posterior to



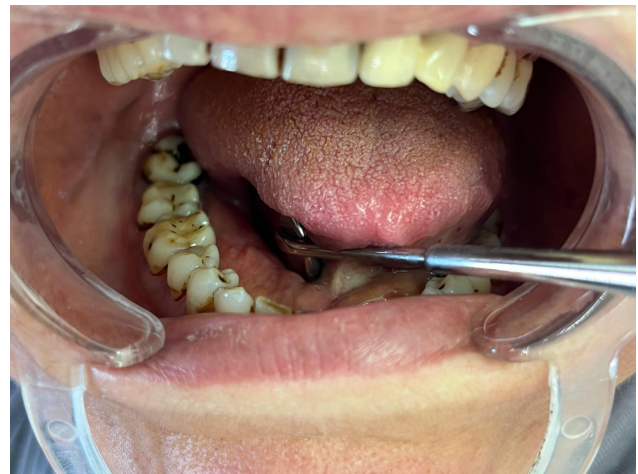

**Figure 5.** Detailed analysis with sequential cross-sectional images moving from posterior to anterior of the affected area with figure 5A being the most posterior.



**Figure 6.** Excised specimens demonstrates a yellowish-white, rough surface texture with an irregular contour.

the most palpable portion of the sialolith to prevent displacement during the procedure. A single continuous stroke was used to make a 1.5 cm incision, followed by blunt dissection of the surrounding tissues, leading to the extraction of two pieces of sialoliths (Figure 6). After removing the sialoliths, the silk sutures were taken out, and milking the gland facilitated saliva discharge. Interrupted 3.0 silk sutures were placed to close the oral mucosa. Postoperative treatment included prescribing the patient a seven-day course of amoxicillin and clavulanic acid combination at 1000 mg twice daily orally. The patient had an uneventful recovery, and no further issues were reported at the six-month follow-up (Figure 7).



**Figure 7.** Postoperative intraoral appearance at the 6th month follow-up period.

## Discussion

To this date, the pathophysiological pathways of sialolithiasis still remain unknown, and several hypotheses have been advocated on the issue.<sup>1</sup> While one of the theories is related to the existence of intracellular microcalculi being discharged into the canal and then become a nidus for further calcification, the other one posits a mucous plug which occurs in the ductal system, may present the nidus.<sup>5,14</sup> On a common consensus of these hypotheses, it is believed that formation mechanism of the sialolithiasis is related to accumulation of calcium salts around an initial organic nidus.<sup>1,5,14</sup> Moreover, there is another possible hypothesis that supposes the formation of sialolithiasis may be initiated by the migration of alimentary substances or oral microorganisms into the salivary ductal system.<sup>5,14</sup>

The submandibular gland is most frequently involved (around 80% of cases), followed by parotid (5%–20%) and, rarely, minor glands (1%–2%). The reason for the submandibular gland being the most involved can be directly linked to its retrograde anatomical location and tortuous anatomy of the duct combined with the secretion of mucous and more alkaline saliva with a major concentration of calcium.<sup>15</sup> In this report, as we described a case of a two-piece sialolith of unusual size and shape that occurred in the submandibular gland duct, it could be seen that the occurrence of the sialolithiasis found in the consulted reports is in line with our case report.

The previous case reports and meta-analysis indicate that sialolithiasis occurs with higher frequency in males and in individuals from 30–40 years of age.<sup>16</sup> However, these cases could also affect both the younger and older patients, as well as children albeit rarely.<sup>12,17</sup> Similarly, a recent case series report documented three cases of submandibular sialolithiasis in patients aged 19, 40, and 65 years.<sup>18</sup> Consistent with these findings, in a prospective non-randomized study<sup>19</sup>, the researchers evaluated the quality of life after the treatment of sialolithiasis, and the mean age was of 44.7 years. In a case series report analyzing 46 patients with submandibular sialoliths, the mean age was 37.3 for male and 34.6 for female patients.<sup>20</sup> In this case report, the patient was 51-year old.

Notably, sialolithiasis predominantly occurs unilaterally and is usually found as a single formation, though multiple formations are rare.<sup>11,12</sup> Single sialolithiasis was detected in 75.3% of cases, while multiple sialolithiasis, including dual and triple formations, represent rare occurrences with percentages of 15.6% and 2.9%, respectively.<sup>12,13</sup> Multiple sialolithiasis in the submandibular duct are indeed referred to as rare entities in the literature. Additionally, it is observed that the size of sialoliths can range from less than 1mm to several centimeters.<sup>21,22</sup> The sialoliths that reached 1cm or surpassed 1.5 cm in any diameter are referred to as being rare

and giant or unusually large, respectively.<sup>1,23</sup> In a case report<sup>21</sup>, a 49-year-old male patient was presented with 8 sialoliths each of approximately 2 mm in diameter within the submandibular duct. In the same case report, the authors cited the work of Brusati and Fiamminghi<sup>24</sup>, who documented the removal of 2 sialoliths measuring 6 × 8 mm and 27 × 31 mm, respectively. In the present study, the sialolithiasis were identified unilaterally, representing a quite common finding in the literature. However, the current case could be considered to be rare and giant in the pertinent medical literature due to both bipartite characterization and dimensions.

It was also observed that the present case's morphology depict a plano-convex shape rather than a cylindrical shape for the bigger piece, and it was cylindrical for the smaller piece. The sialolithiasis could be of spindle, cylindrical, or spherical shapes and exhibits a yellowish-brown hue or grayish-white hue.<sup>12</sup> Each of these types has the ability to show the distinctive features or characteristics associated with the anatomic location where the calculi has occurred.<sup>12</sup> For instance, if the sialolithiasis is lodged within the duct of the salivary gland, it tends to depict an elongated or a cylindrical morphology. However, when it is located in the salivary gland, it is more inclined to take on a circular shape.<sup>12,25</sup>

In the treatment of sialolithiasis, therapeutic approaches are categorized into traditional and modern methods.<sup>26,27</sup> The remarkable advancement of technology in recent years has led to replacing more aggressive methods with minimally invasive procedures. Notably, the preservation of glandular function is of the utmost importance in clinical success, so clinicians need to be familiar with all techniques. In cases of small sialolithiasis, conservative management comprising sialogogues and glandular massage may be sufficient for therapeutic success; however, surgical intervention is indicated for larger ones. Regarding sialolithiasis in the submandibular duct or gland, the selection of surgical or non-surgical treatment approaches is influenced by several critical factors.<sup>5,14,26</sup> If a submandibular sialolithiasis located near the Wharton papilla, the sialodochoplasty as a marsupialization method is performed before the stone is removed via an intraoral sialolithotomy approach. On a general note, submandibular sialoliths located anterior to the first molar tooth may be removed through intraoral sialolithotomy when they are palpable. In line with this, Bozkurt et al.<sup>27</sup> emphasized that primary treatment for sialolithiasis that are easily palpable and located at the distal portion of the duct should be removed via sialolithotomy. If there are recurrent episodes of obstruction and sialadenitis subsequent to intraoral sialolithotomy, which is unlikely to resolve with a non-invasive approach alone, excision of the submandibular gland may be considered.<sup>27</sup> Moreover, cases requiring sialoadenectomy rather than a sialolithotomy with intraoral approach include sialolithiasis located posterior to the first molar region or located in the middle part of the Wharton's duct that cannot be bimanually palpable via intraoral examination.<sup>26,27</sup> Sialoadenectomy could be performed by either transcervical approach or intraoral approach; however, some researchers strongly oppose the intraoral approach because of the variable anatomical relationships between the submandibular gland, the lingual nerve, Wharton's duct, and hypoglossal nerve in the oral cavity, as well as the risk of severe hemorrhage from lingual vessels.<sup>28</sup> On the other hand, the transcervical approach presents some potential risks including facial symmetry related to neurological complications, and may result in visible cervical scarring.<sup>28</sup> In this context, the endoscopic approach stands out as both a safe and an effective alternative technique. But since endoscopic approach is generally recommended for stones that are less than 4 mm in diameter, we opted for surgical removal in this case. Alternatively, endoscopy combined with lithotripsy could have been another treatment option for this case as sialoliths of the submandibular duct measuring 5–7 mm in diameter may be fragmented using endoscopic-guided laser lithotripsy before manual removal.<sup>29</sup> In a comprehensive retrospective study, Ayrancı et al.<sup>30</sup> evaluated the outcomes of minimally invasive transoral approaches

for the management of sialoliths at various locations within Wharton's duct. In their study, they pointed that transoral approaches may demonstrate superior efficacy in managing Wharton's duct sialoliths because of offering both higher success rates and broader therapeutic applications compared to conservative intervention like sialendoscopy. On the other hand, as a contemporary approach, transoral robotic surgery (TORS) enables the excision of ranulas in the floor of the mouth, sialoliths, and salivary gland tumors in the submandibular gland and oropharynx.<sup>30</sup> The implementation of TORS represents an innovative alternative to conventional open approaches for salivary gland pathologies, offering enhanced surgical access, better cosmetic outcomes with minimal scarring, reduced blood loss, shortened hospitalization, and overall decreased morbidity.<sup>30</sup> This alternative treatment modality requires both a high level of dedicated experience and equipment. Unfortunately our clinic lacks these sophisticated equipment, which can be considered as a limitation for this case report. In the current case, the sialolith could be palpated easily from the intraoral region, even though it extended to the posterior region of the first molar, so an intraoral sialolithotomy was effectively performed with no injury to the lingual nerve.

## Conclusion

In conclusion, this case illustrates the management of sialolithiasis with two separate stones in the submandibular gland's duct through a traditional surgical approach. The presence of two sialoliths within the duct and thorough preoperative planning make this case notable. The positive outcome was due to detailed diagnostic imaging before surgery, a careful surgical approach tailored to the anatomical location of the sialoliths during the operation, and maintenance of normal gland function postoperatively. This case aligns with literature advocating for minimally invasive approaches when possible and emphasizes the importance of long-term follow-up. Long-term follow-up showed no recurrence and complete resolution of symptoms, indicating that proper surgical planning and removal of the sialolith can lead to favorable outcomes in complex cases of multiple sialoliths.

## Ethical Approval

Ethical approval was not obtained for this case report. However, the patient voluntarily agreed to participate and signed a written informed consent form.

## Acknowledgements

We thank our dental assistant and nurse (Mumine Uzuncaok) from Istanbul University-Cerrahpaşa Faculty of Dentistry, Department of Oral and Maxillofacial Surgery Clinic.

## Author Contributions

Diagnosed the condition : N.M.T.  
Surgical planning and study design : All Authors  
Wrote the manuscript : All Authors  
Read and approved the final manuscript : All Authors

## Conflict of Interest

No potential conflict of interest relevant to this article was reported.



## Authors' ORCID(s)

N.M.T. 0000-0002-5595-9302

A.E.T. 0000-0002-9156-9109

## References

- Oliveira Tde P, Oliveira IN, Pinheiro EC, Gomes RC, Mainenti P. Giant sialolith of submandibular gland duct treated by excision and ductal repair: a case report. *Braz J Otorhinolaryngol*. 2016;82(1):112–115. doi:10.1016/j.bjorl.2015.03.013.
- Hammett JT, Walker C. In: *Sialolithiasis*. Treasure Island (FL): StatPearls Publishing Copyright © 2025, StatPearls Publishing LLC.; 2025. .
- Huoh KC, Eisele DW. Etiologic factors in sialolithiasis. *Otolaryngol Head Neck Surg*. 2011;145(6):935–939. doi:10.1177/0194599811415489.
- Rosales Diaz Miron D, Castillo B, Rodriguez-Pulido J. Gland excision in submandibular sialolithiasis: A case report. *Journal of Oral Research*. 2015;4:270–274. doi:10.17126/joralres.2015.052.
- Marchal F, Kurt AM, Dulguerov P, Lehmann W. Retrograde theory in sialolithiasis formation. *Arch Otolaryngol Head Neck Surg*. 2001;127(1):66–68. doi:10.1001/archotol.127.1.66.
- Harrison JD. Causes, natural history, and incidence of salivary stones and obstructions. *Otolaryngol Clin North Am*. 2009;42(6):927–947, Table of Contents. doi:10.1016/j.otc.2009.08.012.
- Rzyska-Grala I, Stopa Z, Grala B, Gołębiowski M, Wanyura H, Zuchowska A, et al. Salivary gland calculi - contemporary methods of imaging. *Pol J Radiol*. 2010;75(3):25–37.
- Mao JS, Lee YC, Chi JC, Yi WL, Tsou YA, Lin CD, et al. Long-term rare giant sialolithiasis for 30 years: A case report and review of literature. *World J Clin Cases*. 2023;11(22):5382–5390. doi:10.12998/wjcc.v11.i22.5382.
- Yiu AJ, Kalejaiye A, Amdur RL, Todd Hesham HN, Bandyopadhyay BC. Association of serum electrolytes and smoking with salivary gland stone formation. *Int J Oral Maxillofac Surg*. 2016;45(6):764–768. doi:10.1016/j.ijom.2016.02.007.
- Sonar PR, Panchbhai A, Dhole P. Sialolithiasis in the Left Submandibular Gland: A Case. *Cureus*. 2023;15(11):e48999. doi:10.7759/cureus.48999.
- Jáuregui E, Kiringoda R, Ryan WR, Eisele DW, Chang JL. Chronic parotitis with multiple calcifications: Clinical and sialendoscopic findings. *Laryngoscope*. 2017;127(7):1565–1570. doi:10.1002/lary.26386.
- Silveira Junior JBd, Matias Neto JB, Andrade Junior I, Capistrano HM. Multiple sialolithiasis in submandibular gland duct: a rare case report. *RGÖ - Rev Gaúcha Odontol*. 2020;68. doi:10.1590/1981-863720200002920180103.
- Foletti JM, Graillon N, Avignon S, Guyot L, Chossegros C. Salivary Calculi Removal by Minimally Invasive Techniques: A Decision Tree Based on the Diameter of the Calculi and Their Position in the Excretory Duct. *J Oral Maxillofac Surg*. 2018;76(1):112–118. doi:10.1016/j.joms.2017.06.009.
- Marchal F, Dulguerov P. Sialolithiasis management: the state of the art. *Arch Otolaryngol Head Neck Surg*. 2003;129(9):951–956. doi:10.1001/archotol.129.9.951.
- Aoun G, Maksoud C. Sialolith of Unusual Size and Shape in the Anterior Segment of the Submandibular Duct. *Cureus*. 2022;14(4):e24114. doi:10.7759/cureus.24114.
- Sigismund PE, Zenk J, Koch M, Schapher M, Rudes M, Iro H. Nearly 3,000 salivary stones: some clinical and epidemiologic aspects. *Laryngoscope*. 2015;125(8):1879–1882. doi:10.1002/lary.25377.
- Krishnappa BD. Multiple submandibular duct (Wharton's duct) calculi of unusual size and shape. *Indian J Otolaryngol Head Neck Surg*. 2010;62(1):88–89. doi:10.1007/s12070-010-0018-4.
- Uğur TA, Yılmaz S. Üç Varyasyonuyla Submandibular Tükürük Bezi Taşları: Olgu Serisi. *Akd Dent J*. 2023;2(2):110–114.
- Melo GM, Neves MC, Rosano M, Vanni C, Abrahao M, Cervantes O. Quality of life after sialendoscopy: prospective non-randomized study. *BMC Surg*. 2022;22(1):11. doi:10.1186/s12893-021-01462-2.
- Buyruk A, Bozkuş F. Submandibular Bez Cerrahi Sonuçlarımız. *Harran univ tıp fak derg*. 2020;17(1):45–49. doi:10.35440/hutfd.651611.
- Leung AK, Choi MC, Wagner GA. Multiple sialoliths and a sialolith of unusual size in the submandibular duct: a case report. *Oral Surg Oral Med Oral Pathol Oral Radiol Endod*. 1999;87(3):331–333. doi:10.1016/s1079-2104(99)70218-0.
- Moon PP, Bankar M, Kalambe S, Badge A, Kukde MM, Bankar NJ. An Unusually Large Submandibular Sialolith: A Case Report. *Cureus*. 2024;16(9):e70356. doi:10.7759/cureus.70356.
- Huang TC, Dalton JB, Monsour FN, Savage NW. Multiple, large sialoliths of the submandibular gland duct: a case report. *Aust Dent J*. 2009;54(1):61–65. doi:10.1111/j.1834-7819.2008.01091.x.
- Brusati R, Fiamminghi L. Large calculus of the submandibular gland: report of case. *J Oral Surg*. 1973;31(9):710–1.
- Xiao JQ, Sun HJ, Qiao QH, Bao X, Wu CB, Zhou Q. Evaluation of Sialendoscopy-Assisted Treatment of Submandibular Gland Stones. *J Oral Maxillofac Surg*. 2017;75(2):309–316. doi:10.1016/j.joms.2016.08.023.
- Cumpston E, Chen P. In: *Submandibular Excision*. Treasure Island (FL): StatPearls Publishing Copyright © 2025, StatPearls Publishing LLC.; 2025. .
- Bozkurt P, Kolsuz M, Erdem E. Large Sialolith of the Submandibular Gland: Report of a Case and Comparison of Sialolithotomy VS Sialoadenectomy. *SDU J Health Sci*. 2016;7(1):41–43. doi:10.22312/sbed.28024.
- Singh PP, Goyal M. Our Experience with Intraoral Submandibular Gland Excision. *Indian J Otolaryngol Head Neck Surg*. 2020;72(3):297–301. doi:10.1007/s12070-019-01784-x.
- Kahveci K, Ayrancı F. Retrospective Evaluation of the Treatment of Wharton's Duct Stones with Transoral Approach. *Middle Black Sea J Health Sci*. 2019;5(2):74–78. doi:10.19127/mbsjohs.555748.
- Özen AB, Kırkpınar A, Karaca IR. Sialolithiazis Vakalarında Cerrahi Yaklaşımlar ve Klinik Çalışmalar. *ADO J Clin Sci*. 2024;13(2):388–394. doi:10.54617/adoklinikbilimler.1379003.