

## Clinical, Radiological and Hematological Evaluation in Cats with Tooth Resorption

Selman PULAT<sup>1,a,✉</sup>, Kurtuluş PARLAK<sup>1,b</sup>

<sup>1</sup>Department of Surgery, Faculty of Veterinary Medicine, Selçuk University, Konya, TÜRKİYE

ORCID: <sup>a</sup>0009-0004-3874-8337, <sup>b</sup>0000-0002-8656-037X

### ✉ Corresponding Author

Selman PULAT

Department of Surgery, Faculty of  
Veterinary Medicine, Selçuk  
University, Konya, TÜRKİYE

selmanpulatt54@gmail.com

Received  
10.12.2024

Accepted  
17.02.2025

Published  
30.06.2025

DOI  
10.47027/duvetfd.1599449

**How to cite: Pulat S, Parlak K (2025).**  
Clinical, radiological and  
hematological evaluation in cats with  
tooth resorption. *Dicle Univ Vet Fak*  
*Derg.*, 18(1):6-12.

This journal is licensed under a Creative Commons Attribution-Non Commercial 4.0 International License ([CC BY-NC 4.0](https://creativecommons.org/licenses/by-nc/4.0/)).



### Abstract

This study aimed to investigate tooth resorption (TR), a common dental disease in cats. Conducted on 35 cats admitted to Selçuk University Faculty of Veterinary Medicine Animal Hospital for oral health issues or castration, the study evaluated the prevalence of TR, the distribution of affected teeth, and the relationship between resorption types and stages. Clinical and radiographic examinations were performed, and blood parameters were analyzed. The findings indicated that TR prevalence increases with age and is most commonly observed in mandibular third premolars and first molars. Blood analyses revealed sodium and phosphorus levels outside the reference ranges in many cases, suggesting electrolyte and metabolic imbalances. A significant relationship was observed between TR stages and types; Type 1 lesions were predominant in early stages, while Type 3 lesions increased in advanced stages. In conclusion, TR is not solely a localized periodontal condition but also has systemic effects. A multidisciplinary approach is recommended for the early diagnosis and prevention of TR progression. Further investigation of environmental, genetic, and metabolic factors may contribute to the development of effective management strategies for this disease.

**Key Words:** Cat, dental radiography, tooth resorption

### Diş Rezorpsiyonlu Kedilerde Klinik, Radyolojik ve Hematolojik Değerlendirme

#### Öz

Bu çalışmanın amacı kedilerde yaygın bir diş hastalığı olan diş rezorpsiyonunu (TR) araştırmaktır. Selçuk Üniversitesi Veteriner Fakültesi Hayvan Hastanesi'ne ağız sağlığı sorunları veya kastrasyon nedeniyle başvuran 35 kedi üzerinde yürütülen çalışmada, TR'nin yaygınlığı, etkilenen dişlerin dağılımı ve rezorpsiyon tipleri ile evreleri arasındaki ilişki değerlendirildi. Klinik ve radyografik muayeneler yapıldı ve kan parametreleri analiz edildi. Bulgular TR prevalansının yaşla birlikte arttığını ve en yaygın olarak mandibular üçüncü premolar ve birinci molar dişlerde görüldüğünü göstermiştir. Kan analizleri, birçok vakada referans aralıklarının dışında sodyum ve fosfor seviyeleri ortaya çıkarmış, bu da elektrolit ve metabolik dengesizlikleri düşündürmüştür. TR evreleri ve tipleri arasında anlamlı bir ilişki gözlenmiştir; Tip 1 lezyonlar erken evrelerde baskınken, Tip 3 lezyonlar ileri evrelerde artmıştır. Sonuç olarak, TR sadece lokalize bir periodontal durum olmayıp sistemik etkileri de vardır. TR'nin erken teşhisi ve ilerlemesinin önlenmesi için multidisipliner bir yaklaşım önerilmektedir. Çevresel, genetik ve metabolik faktörlerin daha fazla araştırılması, bu hastalık için etkili yönetim stratejilerinin geliştirilmesine katkıda bulunabilir.

**Anahtar Kelimeler:** Dental radyografi, diş rezorpsiyonu, kedi

## INTRODUCTION

Tooth resorption (TR) is a common and important dental disease in cats. The term tooth resorption has been named in different ways from past to present, but the term “tooth resorption (TR)” accepted by the American Veterinary Dental College (AVDC) is the most commonly used one (1). The disease is characterized by a resorption of the cementum layer or enamel surface of the tooth caused by polynuclear cells called odontoclasts. As a result of tooth root loss, tooth destruction destabilizes the crown, causing it to fracture (2-4). The disease is diagnosed based on clinical examination and radiographic findings (3). It has been reported that the prevalence of tooth resorption in domestic cats ranges from 20% to 75% and both the incidence and the number of affected teeth increase with age (5-6).

A number of predisposing factors for TR have been identified. The most widely documented association in the literature is increasing age (3,5). Other associations investigated include bacteria in dental plaque, diet (high acidity in dry foods damages both enamel and cementum, and overfeeding with raw liver may contribute to the disease because both retinol and tretinoin in liver can directly stimulate the activity of clastic cells.), the presence of occlusal stress that can cause microfractures on the surface of the cementum (these microfractures can cause inflammation of the cementum or periodontal ligament and the attraction of odontoclasts, leading to TR), and even acid regurgitation of hairballs can cause lesions in these hard tissues (3,7-9). In addition, the consistency of commercial cat foods may affect the functional integrity of the periodontal ligament, leading to tooth resorption, and Ca or Mg deficiency has also been reported in affected cats (10,11). Studies have suggested that TR lesions in cats are associated with *feline immunodeficiency virus (FIV)* and *feline herpes virus-1 (FHV-1)*, but the results are controversial due to the lack of material in the studies and the fact that the study was not supported by dental x-rays (12). Another study showed that there was no association between TR and *feline calicivirus (FCV)* (13,14).

The relationship between TR and other dental diseases is complex. It has been reported that cats with dental diseases (gingivitis, tartar or periodontal disease) have a four to five times higher risk of resorptive lesions than those without previous dental disease (15).

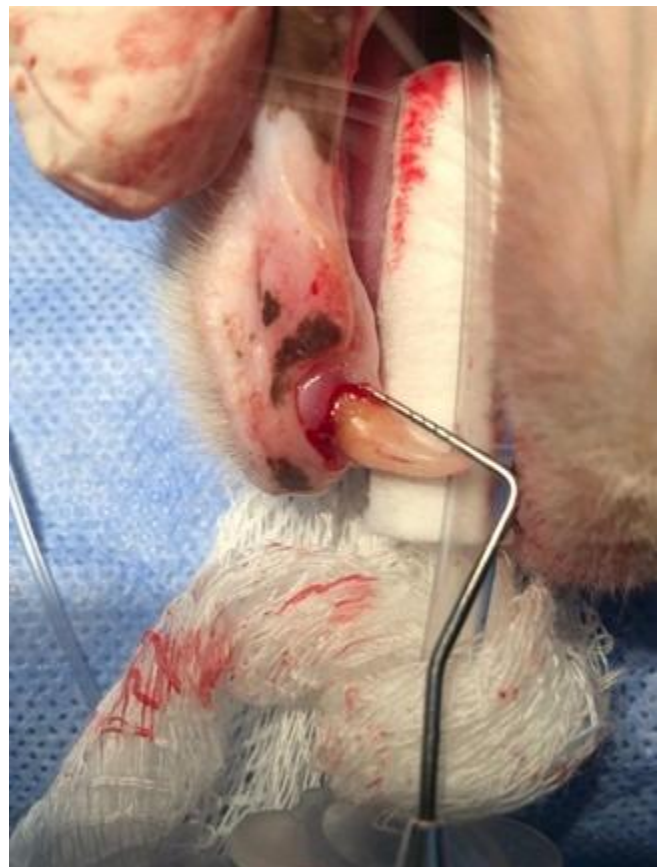It has been suggested that systemic disorders may also be associated with TR in cats. The calcium-vitamin D-parathyroid hormone (PTH) system is involved in the activation of osteoclastic bone resorption; however, only serum concentration of 25-hydroxyvitamin D (25-OHD) has been associated with TR. The role of the calcium-vitamin D PTH system in the formation of TR remains unclear (9,16).

The aim of this study was to evaluate the prevalence of TR, the distribution of affected teeth and the relationship between the types and stages of resorption in cats diagnosed with tooth resorption (TR) by intraoral radiographic examination, clinical examination and laboratory analysis.

## MATERIAL AND METHODS

The material of this study consisted of cats that were admitted to Selçuk University, Faculty of Veterinary Medicine Animal Hospital with oral problems or were anesthetized for

castration. A total of 35 cats older than 1 year with different breed, sex and body weight characteristics were included in the study, which were diagnosed with tooth resorption after clinical and radiographic examinations. After taking anamnesis for each patient, a comprehensive physical examination was performed and the findings were recorded on a standardized examination form. Blood samples were taken for hematological measurements (blood gas analysis, complete blood count and serum biochemistry profiles) and detailed clinical and radiographic examinations were performed under sedation or general anesthesia. Owners were informed in detail about the purpose of the study, the procedures to be performed and the potential risks, and a signed consent form was obtained indicating that they consented to the inclusion of their cats in the study. The diagnosis of tooth resorption was based on the results of anamnesis, clinical examination and intraoral radiographic evaluations (Figure 1).



**Figure 1.** Clinical examination of tooth 404 with dental probe in a cat with tooth resorption

## Anesthesia Administration

For the diagnosis of resorptive lesions, all cats underwent sedation and general anesthesia. Induction of anesthesia was achieved using a combination of 0.4 mg/kg butorphanol hydrogen tartrate (Butomidor® 10 mg/ml, Richter Pharma, Austria) and 0.05 mg/kg medetomidine hydrochloride (Domitor®, Orion Pharma, Finland) intramuscularly. Subsequently, general anesthesia was induced by intravenous (IV) administration of 4 mg/kg propofol (Propofol-Lipuro 1% [10 mg/ml], B. Braun, Portugal). Under anesthesia, intraoral radiographic scans were performed and safety and stabilization of the cats were ensured during radiographic imaging. At the same time, the necessary samples were taken for laboratory analysis. After completion of the procedures, the

cats were safely awakened from anesthesia by intramuscular injection of 0.125 mg/kg atipamezole hydrochloride (Antisedan® 5 mg/ml, Orion Pharma, Finland).

### Radiographic Examination

X-rays of each cat's teeth were taken and digitally recorded using parallel technique, bisection angle technique (17) and simplified technique (18,19) with Planmeca Pro-X Periapical X-Ray Device DC, Planmeca ProSensor RVG device (Size: 1) and Planmeca Romexis software patient tracking and imaging software program (Figure 2). The radiographic images were recorded on the examination forms by determining the types and stages of resorption for each tooth based on the anatomical and radiological classification system of AVDC.

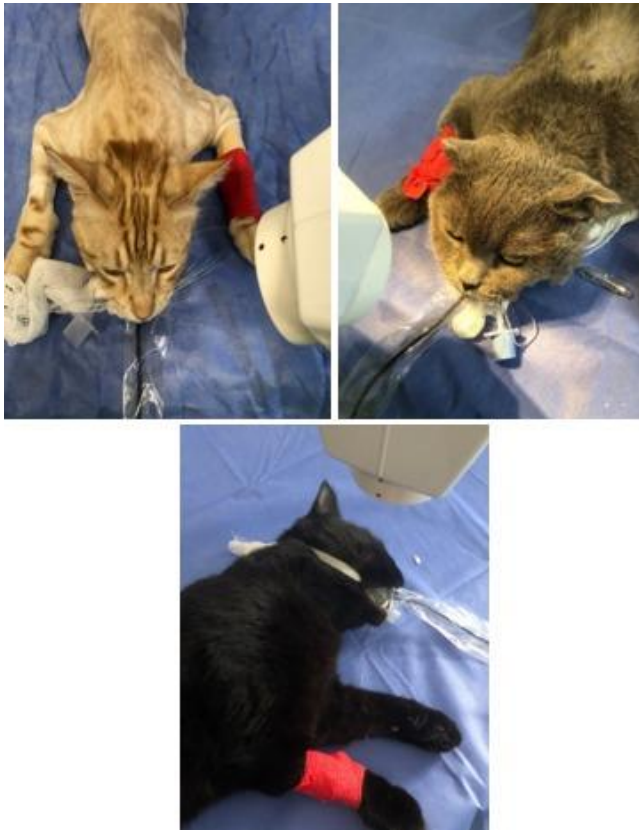

Figure 2. Dental X-ray

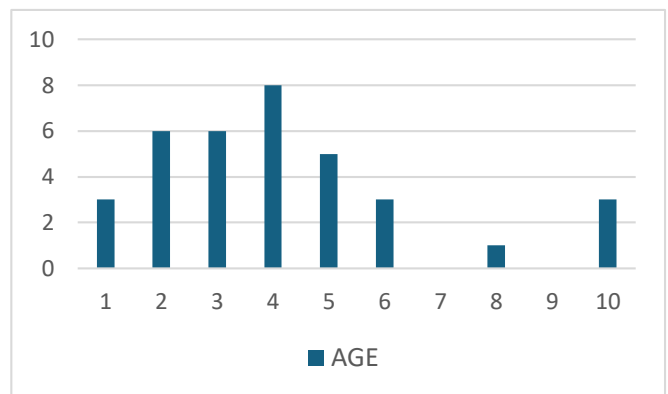
### Statistical Analysis

Age, sex, breed distribution and teeth affected by tooth resorption in cats diagnosed with TR were evaluated by calculating the mean. Chi-square analysis was performed to evaluate the relationship between TR stage and TR type in the teeth diagnosed with TR.

### RESULTS

The mean age of the 35 cats diagnosed with tooth resorption was 4.17 (years) (Chart 1), gender distribution was 19 males (54.2%) and 16 females (45.7%); breed distribution was 20 Domestic Short Hair mixed breed (57%), 7 British (20%), 2 Van Cat (5.7%), 2 Siamese (5.7%), 2 Scottish Fold (5.7%), 1 Persian (2.8%) and 1 Bombay (2.8%). The diet of the cats was as follows: mixed diet (65.7%) (home cooked diet, dry food and wet food), dry food (17.1%), dry and wet food together (17.1%). It was determined that 60% of the cats were vaccinated and 40% were unvaccinated.

Chart 1. Age distribution of cats with TR



In the routine clinical examination of 35 cats with TR, type 2 resorption (38.21%), followed by type 1 (36.94%) and type 3 (24.84%) resorption according to AVDC scoring was found most frequently (Figure 3). The highest rate of tooth resorption was observed in tooth 409 (15.28%). This was followed by teeth 309 (8.91%), 407 (8.28%), 108 (8.28%), 307 (7.64%), 408 (6.36%), 308 (6.36%) and 208 (6.36%) (Table 1).

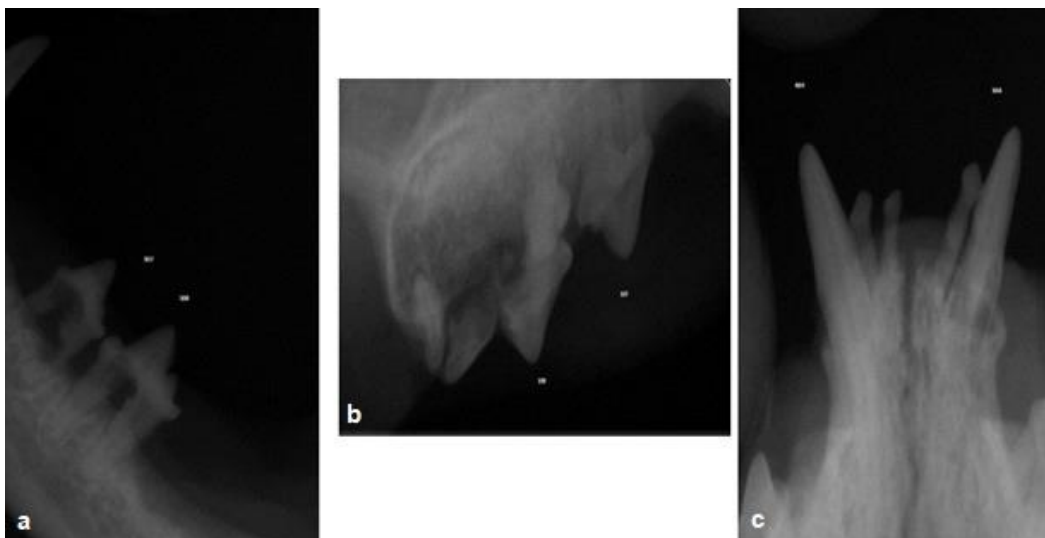


Figure 3. A: Type 1 resorption in teeth 307 and 308. B: Stage 4 and Type 3 resorption in tooth 108, C: Type 2 resorption in teeth 304 and 404.

**Table 1.** Percentages of 157 teeth diagnosed with tooth resorption according to Modified Triadan Numbering

Modified Triadan Tooth Numbering	Affected by TR (n=157)
102	157/1 (0.63%)
103	157/1 (0.63%)
104	157/8 (5.09%)
201	157/1 (0.63%)
202	157/2 (1.27%)
204	157/7 (4.45%)
301	157/1 (0.63%)
302	157/1 (0.63%)
303	157/1 (0.63%)
304	157/9 (5.73%)
403	157/1 (0.63%)
404	157/8 (5.09%)
107	157/4 (2.54%)
108	157/13 (8.28%)
206	157/1 (0.63%)
207	157/4 (2.54%)
208	157/10 (6.36%)
307	157/12 (7.64%)
308	157/10 (6.36%)
309	157/14 (8.91%)
407	157/13 (8.28%)
408	157/10 (6.36%)
409	157/24 (15.28%)

In this study, blood parameters of 35 cats diagnosed with TR were analysed and the results were evaluated for compliance with reference ranges. Although most parameters were within the reference ranges, some parameters showed significant deviations. WBC levels exceeded the reference range in 22%, sodium (Na) levels in 85%, calcium (Ca) levels in 48% and glucose levels in 14% of cases. On the other hand, pH levels fell below the reference range in 31% and HB levels in 5% of cases. These findings indicate that marked changes in some haematological and biochemical parameters may occur in cats diagnosed with TR.

When chi-square analysis was performed to examine the relationship between TR stage and TR type, a significant relationship was found between TR stage and TR type evaluated on the same tooth ( $\chi^2 = 83.052$ ;  $df = 12$ ;  $P < 0.001$ ). A moderate relationship was found (Cramer's V = 0.514;  $P < 0.001$ ). TR Type 1 was more prevalent in teeth in Stages 1 and 2. Fifty percent of the teeth in Stage 1 and 28.5% of the teeth in Stage 2 were classified as TR Type 1. TR Type 3 was more predominant in teeth in Stages 3, 4 and 5. 28.5% of the teeth in Stage 3, 60-100% of the teeth in Stage 4 (4a, 4b, 4c) and 100% of the teeth in Stage 5 were classified as TR Type 3. These results suggest that tooth resorption may be associated with different TR types as it progresses and that TR Type 3 is more predominant in advanced stages (Table 2).

**Table 2.** Relationship between DR stage and DR type according to the number of resorbed teeth

TR Type	TR Stage						
	1 (n=4)	2 (n=42)	3 (n=7)	4a (n=3)	4b (n=5)	4c (n=85)	5 (n=11)
1	2/4 <sup>ab</sup> (%50)	21/42 <sup>ab</sup> (%50)	5/7 <sup>b</sup> (%71.4)	1/3 <sup>abc</sup> (%33.3)	1/5 <sup>abc</sup> (%20)	5/85 <sup>c</sup> (%5.85)	-
2	2/4 <sup>a</sup> (%50)	12/42 <sup>a</sup> (%28.5)	-	-	1/5 <sup>ab</sup> (%20)	4/85 <sup>b</sup> (%4.70)	-
3	-	9/42 <sup>a</sup> (%21.4)	2/7 <sup>a</sup> (%28.5)	2/3 <sup>ab</sup> (%66.6)	3/5 <sup>ab</sup> (%60)	76/85 <sup>b</sup> (%89.4)	11/11 <sup>b</sup> (%100)

Values with different superscripts in a row are significantly different at  $p < 0.05$ .

## DISCUSSION AND CONCLUSION

In this study, the diagnosis of TR was first made by clinical examination of the teeth with a dental probe and then confirmed by radiographic examinations. In a study by Eriksson et al. (20), the sensitivity of dental radiography was reported as 78.9% and specificity as 100%, while the sensitivity of oral clinical examination was only 36.0% and specificity as 99.9%. These findings suggest that TR in cats is much more common than expected and that cases that may be missed on clinical examination can be easily detected by radiographic evaluation. In cats with suspected TR, dental radiographic examination is strongly recommended to confirm the diagnosis.

Previous studies have demonstrated that both the prevalence and the number of teeth affected by tooth resorption in cats increase with advancing age (10,21). Furthermore, it has been reported that the risk of developing resorptive lesions rises by 1.78 times with each additional year of age (21). In the present study, all cats included were aged one year or older, with the mean age of cats in the tooth resorption (TR) group calculated to be 4.17 years. This finding is in parallel with the literature reporting that the incidence of TR increases with age (22). However, the fact that TR cases were detected even in 1-year-old cats in our study indicates

that this disease may start at an earlier age. This was also emphasized by DeLaurier et al. (23) in a histologic study of early resorptive lesions. However, O'Neill et al. (24) found that the median age of cats with TR (9.47 years) was significantly higher than that of cats without TR (4.94 years) and stated that age is one of the strongest risk factors for TR. In our study, regular dental check-ups from a young age are recommended for early diagnosis of TR and prevention of its progression.

In terms of breed factor, the highest prevalence of TR was found in Domestic Short Hair (48.5%) and British (20%) breeds in our study. Similarly, O'Neill et al. (24) reported a high prevalence of TR in Siamese (18.7%) and suggested that some races may have a genetic predisposition to this disease. However, Gorrel (4) emphasized that conflicting results regarding racial predisposition have been reported in different studies. While some studies have suggested that TR is more common in certain breeds (21), other studies have reported that the difference between breeds is not significant (23). These contradictions suggest that in addition to genetic factors, environmental conditions, care practices and dietary habits may also play an important role in the development



of TR. For example, Gorrel and Larsson (10) discussed the potential impact of environmental and diet-related factors on the incidence of TR and reported that consumption of hard food may reduce the risk of TR in some breeds. The literature suggests that diets high in carbohydrate content are associated with an increased risk of periodontal diseases and may indirectly contribute to the development of TR (21). In our study, the highest prevalence of TR was observed in mixed-breed cats, which may reflect not only a potential genetic predisposition but also the influence of environmental factors and care practices. Mixed-breed cats typically exhibit greater genetic diversity, which could interact with external factors such as diet, living conditions, and overall care to increase susceptibility to TR. On the other hand, the high prevalence observed in the British breed supports the importance of genetic factors since this breed is a more genetically homogeneous population. These findings suggest that TR is not only a genetic disease, but also environmental and management factors need to be considered. In order to obtain more comprehensive results, genetic analyses among different breeds and large-scale studies evaluating the impact of environmental factors will be needed.

Of the 35 cats with tooth resorption evaluated, 16 were neutered (45.7%) and 19 were not neutered (54.3%). This suggests the possibility that neutering may have a significant effect on the development of TR. In the literature, the effects of neutering on metabolism and the incidence of some systemic diseases have been reported. For example, Whyte et al. (25) suggested that obesity, insulin resistance and low movement levels may increase the risk of TR in neutered cats. On the other hand, it is known that higher levels of testosterone and estrogen in unneutered cats may play a role in the preservation of tooth and bone tissue (4). These findings suggest that more extensive studies are needed to understand the effects of neutering on the development of TR.

In our study, the majority of cats with tooth resorption (TR) were found to be fed a mixed diet (48.6%), while 31.4% were fed exclusively dry food, and 20% were provided with a combination of dry and wet food. These findings highlight the potential role of diet in influencing dental health. Gorrel and Larsson (10) reported that hard structured kibble mechanically cleans tooth surfaces and reduces plaque formation. However, it has been reported that mixed and wet food consumption may lead to more plaque and tartar accumulation on the tooth surface, which may increase the risk of TR (21). In our study, mixed diet was more common among cats with TR, indicating that more research is needed to understand the role of diet in the pathogenesis of TR.

When the vaccination schedule was evaluated, it was determined that 45.7% of the cats diagnosed with TR were vaccinated regularly, while 54.3% were vaccinated irregularly or not vaccinated at all. The positive effects of vaccination on systemic immunity may also be important for dental health. Whyte et al. (26) reported a higher incidence of periodontal disease and tooth resorption in immunocompromised cats. In our study, the higher incidence of TR in irregularly vaccinated cats points to the indirect effects of the immune system on the development of TR. This finding suggests that regular vaccination practices may positively affect not only general health but also dental health.

In studies conducted to determine the most commonly affected teeth in terms of tooth resorption in cats, it was observed that some teeth were affected at a higher rate. In a study conducted by Girard et al. (27) on 60 cats, it was reported that TR was most commonly seen on maxillary 3rd and 4th premolars (107, 207, 108, 208) and mandibular 3rd and 4th premolars (307, 407, 308, 408). Similarly, DuPont (28) reported that TR in cats was concentrated on mandibular 3rd and 4th premolars (307, 407, 308, 408) and maxillary 3rd premolars (107, 207) in 67% of cases and mandibular 1st molars (309, 409) were among the most frequently affected teeth. The study also reported that TR was seen in these teeth in 70% of all cases. In a retrospective study by Reiter et al. (9), maxillary 3rd premolars (107, 207) and mandibular 4th premolars (308, 408) were reported to be the most commonly affected teeth and it was emphasized that TR in premolars and molars was more common in older cats. Pistor et al. (29) reported that mandibular 1st molars (309, 409) and maxillary premolars (107, 108, 207, 208) were the teeth most frequently affected by TR. These findings are in agreement with the study by Whyte et al. (26), who reported that TR was most commonly detected in mandibular third premolars (307, 407) and mandibular first molars (309, 409). In addition, Whyte et al. (25) reported that mandibular 3rd premolars (307, 407) and mandibular 1st molars (309) were the teeth at highest risk for TR. In our study, mandibular third premolars (307, 407) and mandibular first molars (309, 409) were the teeth most frequently affected by TR. These findings are consistent with the results reported by Lang et al. (30) regarding the distribution of TR lesions. In particular, mandibular premolars and molars were more frequently affected in terms of TR, supporting the hypothesis that mechanical stress may be higher due to the location and anatomical features of these teeth. These results provide important contributions to understanding the anatomical distribution of TR in cats and emphasize the need for closer examination of specific teeth in the diagnostic process. Future studies may further investigate the environmental and genetic factors affecting the prevalence of TR in these teeth and develop more effective strategies to maintain dental health.

Statistical analyses performed to evaluate the relationship between TR stage and TR type in teeth diagnosed with tooth resorption revealed significant results. The classification system created by AVDC divides TR lesions into two main categories according to anatomical stages and radiographic examination images. This classification provides an important guide for the diagnosis and management of TR in clinical practice (1). Whyte et al. (25) evaluated the relationship between TR stage and TR type and found a statistically significant correlation between these two variables. In our study, when the number of teeth with TR was taken into consideration, it was determined that there was a significant relationship between TR stage and TR type. Our analysis shows that TR Type 1 is more common in teeth in Stages 1 and 2; 50% and 28.5% of these teeth were classified as TR Type 1, respectively. In contrast, TR Type 3 was predominant in Stages 3, 4 and 5. 28.5% of the teeth in Stage 3, 60-100% of the teeth in Stage 4 (4a, 4b, 4c) and 100% of the teeth in Stage 5 were identified as TR Type 3. These findings are consistent with the model proposed by DuPont (31), which explains the progression of TR. These results provide important information about the progression of TR. The findings show that

Type 1 lesions are more common in the initial stages of TR, but as the disease progresses, Type 3 lesions become predominant. This provides valuable data for understanding how anatomical and pathologic changes occur in the progression of TR. Furthermore, these findings may contribute to the development of more targeted treatment strategies by identifying the stage and type in the clinical management of TR.

This study's analysis of blood parameters in cats diagnosed with TR suggests that values outside the reference ranges may be associated with the systemic effects of TR. The elevation of WBC levels beyond the upper limit of the reference range indicates a possible relationship between TR, periodontal inflammation, and systemic inflammatory response (9). In this study, it can be inferred that inflammatory processes were active in cats with elevated WBC levels. Among the electrolyte parameters, Na levels were found to be above the reference range in some cats, with particularly high values of 163 and 167, which were considered indicators of systemic electrolyte imbalances due to cellular and tissue damage (4). Ca levels were also found to be low in several cats, with the lowest recorded value being 0.72. This finding supports the idea of mineral loss in teeth and bone resorption (23). Notably, low calcium levels emphasize the importance of calcium metabolism in the pathogenesis of TR. Low HB levels were also observed, with the lowest recorded HB value being 5.1, suggesting the presence of mild anemia, which could result from chronic inflammation (28). In some cases where glucose levels exceeded 120, transient hyperglycemia was thought to be related to stress or chronic inflammation. Furthermore, decreases in blood pH levels indicate the onset of acidosis. In our study, the pH dropping as low as 7.15 suggests that tooth resorption may disrupt metabolic balance (21). These findings suggest that TR is not confined to local periodontal tissues but has systemic metabolic and hematological effects. They provide important insights into the pathophysiology and progression of TR. This underscores the necessity for TR management and treatment to involve not only local dental interventions but also a holistic approach addressing overall systemic health.

This study presents a comprehensive approach to evaluate factors associated with the etiology and clinical, hematologic and radiographic findings of tooth resorption in cats. A multidisciplinary approach is required for early diagnosis, prevention of progression and effective treatment planning of TR. In future studies, a more detailed examination of environmental and metabolic factors in addition to genetic analysis will contribute to the development of new strategies for the management of the disease.

## ACKNOWLEDGMENT

We would like to thank Research Assistant Hilmiçan Ergin and Dr. Veterinarian Fatma Çuhadar Erdal for their support during the study.

## FINANCIAL SUPPORT

This research is part of a project funded under TÜBİTAK 2209-A programs (Project No. 1919B012203676).

## CONFLICT OF INTEREST

There are no conflicts of interest to be declared by the authors.

## AUTHOR CONTRIBUTIONS

KP, concept and design.

SP, data collection and analysis.

## ETHICAL STATEMENT

This study was carried out with the decision of the Ethics Committee of Selçuk University, Faculty of Veterinary Medicine, Experimental Animal Production and Research Center dated 01.12.2022 and numbered 2022/135.

## REFERENCES

1. **American College of Veterinary Dentistry AVDC nomenclature committee.** Available online: <https://avdc.org/avdc-nomenclature/> (accessed on 23.06.2022).
2. **Lommer MJ, Verstraete FJ (2000).** Prevalence of odontoclastic resorption lesions and periapical radiographic lucencies in cats: 265 cases (1995-1998). *J Am Vet Med Assoc.*, 217(12):1866-1869.
3. **Reiter AM, Mendoza KA (2002).** Feline odontoclastic resorptive lesions: an unsolved enigma in veterinary dentistry. *Vet Clin North Am Small Anim Pract.*, 32(4):791-837.
4. **Gorrel C (2015).** Tooth resorption in cats: pathophysiology and treatment options. *J Feline Med Surg.*, 17(1):37-43.
5. **Imgham K, Gorrel C, Blackburn J, Farnsworth W (2001).** Prevalence of odontoclastic resorptive lesions in a population of clinical healthy cats. *J Small Anim Pract.*, 42:439-443.
6. **Bellows J (2019).** Oral anatomy for the general practitioner In: Small Animal Dental Equipment, Materials, and Techniques. Bellows J (ed). 2nd ed. John Wiley & Sons., Hoboken, USA., 87-112.
7. **Hammarström L, Blomlöf L, Lindskog S (1989).** Dynamics of dento alveolar ankylosis and associated root resorption. *Endod Dent Traumatol.*, 5: 163-175.
8. **Harvey CE, Emily PP, (1993).** Restorative Dentistry. In: Small Animal Dentistry Harvey CE, (ed). Mosby-Year Book, St. Louis, MO, USA., 217-225.
9. **Reiter AM, Lewis JR, Okuda A (2005).** Update on the etiology of tooth resorption in domestic cats. *Vet Clin North Am Small Anim Pract.*, 35:913-942.
10. **Gorrel C, Larsson Å (2002).** Feline odontoclastic resorptive lesions: unveiling the early lesion. *J Small Anim Pract.*, 43(11):482-488.
11. **Harvey CE, Orsini P, McLahan C, Schuster C (2004).** Mapping of the radiographic central point of feline dental resorptive lesions. *J Vet Dent.*, 21(1):15-21.
12. **Hofmann-Lehmann R, Berger M, Sigrist B, Schawalder P, Lutz H (1998).** Feline immunodeficiency virus (FIV) infection leads to increased incidence of feline odontoclastic resorptive lesions (FOLR). *Vet Immunol Immunopathol.*, 65:299-309.
13. **Arx von T, Schawalder P, Ackermann M, Bosshardt DD (2009).** Human and feline invasive cervical resorptions: the missing link? Presentation of four cases. *J Endodon.*, 35:904-913.
14. **Thomas S, Lappin DF, Spears J, Bennett D, Nile C, Riggio MP (2017).** Prevalence of feline calicivirus in cats with odontoclastic resorptive lesions and chronic gingivostomatitis. *Res Vet Sci.*, 111:124-126.

15. **Scarlett JM, Saidla J, Hess J (1999).** Risk factors for odontoclastic resorptive lesions in cats. *J Am Anim Hosp Assoc.*, 35(3):188-192.
16. **Booij-Vrieling HE, Ferbus D, Tryfonidou MA et al (2010).** Increased vitamin D-driven signalling and expression of the vitamin D receptor, MSX2, and RANKL in tooth resorption in cats. *Eur J Oral Sci.*, 118(1):39-46.
17. **Niemiec BA (2014).** Feline dental radiography and radiology: A primer. *J Feline Med Surg.*, 16:887-899.
18. **Woodward TM (2009).** Interpretation of dental radiographs. *Top Companion Anim Med.*, 24:37-43.
19. **Niemiec BA (2010).** Dental radiology. In: Small Animal Dental, Oral and Maxillofacial Disease: A Color Handbook. Niemec (ed). 1st ed. Momson Publishing London, England., 63-87.
20. **Eriksson J, Denwood M, Nielsen SS et al (2024).** Accuracy of three diagnostic tests to detect tooth resorption in unowned unsocialised cats in Denmark. *J Small Anim Pract.*, 65:387-393.
21. **Bellows J (2022).** Feline Dentistry. 2nd ed., John Wiley & Sons., Florida, USA.
22. **Pettersson A, Mannerfelt T (2003).** Prevalence of dental resorptive lesions in Swedish cats. *J Vet Dent.*, 20:140-142.
23. **DeLaurier A, Boyde A, Jackson B, Horton MA, Price JS (2009).** Identifying early osteoclastic resorptive lesions in feline teeth: a model for understanding the origin of multiple idiopathic root resorption. *J Periodontal Res.*, 44:248-257.
24. **O'Neill DG, Gunn-Moore D, Sorrell S et al (2023).** Commonly diagnosed disorders in domestic cats in the UK and their associations with sex and age. *J Feline Med Surg.*, 25(2):1-9.
25. **Whyte A, Tejedor MT, Whyte J, Monteagudo LV, Bonastre C (2021).** Blood parameters and feline tooth resorption: a retrospective case control study from a Spanish University Hospital. *Animals*, 11:2125.
26. **Whyte A, Lacasta S, Whyte J, Monteagudo LV, Tejedor MT (2020).** Tooth resorption in Spanish domestic cats: Preliminary data. *Top Companion Anim Med.*, 38:100369.
27. **Girard N, Servet E, Biourge V, Hennet P (2008).** Feline tooth resorption in a colony of 109 cats. *J Vet Dent.*, 25:166-174.
28. **DuPont G (1995).** Crown amputation with intentional root retention for advanced feline resorptive lesions-a clinical study. *J Vet Dent.*, 12(1):9-13.
29. **Pistor P, Janus I, Janeczek M, Dobrzyński M (2023).** Feline Tooth Resorption: A description of the severity of the disease in regard to animal's age, sex, breed and clinical presentation. *Animals*, 13:2500.
30. **Lang LG, Wilkinson TE, White TL, Farnsworth RK, Potter KA (2016).** Computed tomography of tooth resorption in cats. *Vet Radiol Ultrasound.*, 57:467-474.
31. **DuPont GA (2005).** Radiographic evaluation and treatment of feline dental resorptive lesions. *Vet Clin North Am Small Anim Pract.*, 35:943-962.