

CASE REPORT

# Laparoscopic Pelvic Ring Implant Removal From the Femoroacetabular Joint During Totally Extraperitoneal Herniorrhaphy: A Case Report and Surgical Technique

Cem İlgin Erol<sup>1</sup>  Bilal Karabak<sup>2</sup>  Yavuz Şahbat<sup>2</sup> 

1 Medica Anaşehir International Hospital, Department of General Surgery, İstanbul, Türkiye

2 Erzurum City Hospital, Department of Orthopaedics and Traumatology, Erzurum, Türkiye

## Abstract

Minimally invasive surgeries have become more widespread in recently. Laparoscopy is actively used in many surgeries by general surgeons, urologist, and gynaecologist. Despite this widespread use of laparoscopy, its use in orthopaedic surgeries has not become widespread and as yet is only seen in literature as case reports and series. Fifty-five years old male patient admitted to orthopaedic outpatient clinic with complaints of right hip and inguinal C-shaped pain that had been ongoing for 3 months. Twelve years ago, the patient had undergone open anterior pelvic fixation (ilioinguinal incision) because of a simple type acetabular anterior wall fracture. An incisional hernia due to the previous pelvic surgery and a femoroacetabular screws was detected. There are two treatment options for this case; open implant removal followed by open hernia repair, or open implant removal than laparoscopic hernia repair in a different session. Incisional hernia treatment and femoroacetabular implant remove performed laparoscopically in the same session, and this is first case of literature. In light of this case, laparoscopy seems promising in the management of complications in orthopedic trauma surgery.

**Key words:** Implant removal, laparoscopy, pelvic trauma

## Corresponding Author:

Cem İlgin Erol MD, Department of General Surgery, Medica Anaşehir International Hospital, İstanbul, Turkey  
E-mail: cemilginerol@gmail.com



Content of this journal is licensed under a Creative Commons Attribution-NonCommercial 4.0 International License.

## INTRODUCTION

Minimally invasive surgeries have become more widespread in recent decades (1). Operations that were performed with wide incisions in the past can now be performed mini open or percutaneously to increase patient comfort and reduce complications. With developments in arthroscopic implant technologies and production, tendon and ligament repairs, fracture fixations, removal of foreign bodies, and mass excisions can be performed arthroscopically (2,3). There is a great deal of literature about arthroscopic treatment techniques for the shoulder, knee, and hip joints and implant removal (4, 5) but although fixation methods with percutaneous techniques for pelvic ring injuries have become more widely used, arthroscopic, endoscopic, or laparoscopic techniques for the pelvic ring are limited (6,7).

Laparoscopy is actively used in many surgeries by general surgery, urology, and obstetrics and gynaecology departments. Surgeons can evaluate pelvic internal structures and intervene to abdominal organs during laparoscopy (8). Despite this widespread use of laparoscopy, its use in orthopaedic treatments has not become widespread and as yet is only seen in literature as case reports (9,10). There are 2 case reports in literature showing that laparoscopy can be used in orthopaedic surgery. Francia et al. presented a case where fixation could be made of a fracture in the ramus pubis rather than with anterior incisions, which proved that laparoscopy can be used for treatment purposes in orthopaedic surgery (9). Francia named this technique, "laparoscopic internal fixation" and stated that despite the longer surgical time, blood loss was reduced and hospital stay was shorter. This type of fracture fixation can be difficult because of if case have acute bleeding and acute injury. There may have not been more articles published on this subject as patient died postoperatively. In a case by Thati et al., They explained that laparoscopy can be used in the management of orthopaedic complications in a case report in which the K-wire migrated into the abdomen in the treatment of a femoral proximal fracture was removed laparoscopically (10).

The anterior incisions selected for conventional pelvis surgery can result in some complications such as abdominal organ injuries, major vascular injuries, and abdominal incisional hernia (7). In this technical report, the laparoscopic excision of screws extending to the femoroacetabular joint is described in a patient with

abdominal incision hernia that developed after anterior pelvic incision.

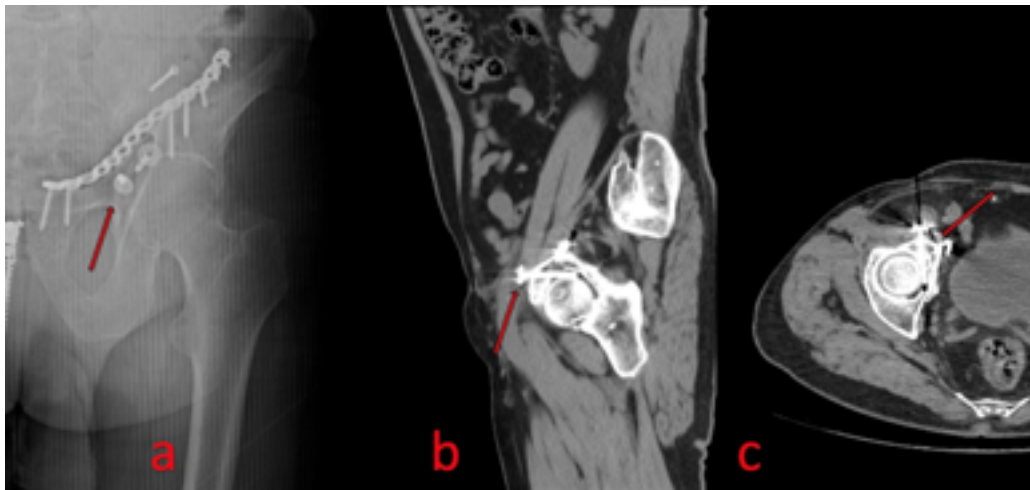
## CASE REPORT

Fifty-five years old male patient admitted to orthopaedic outpatient clinic with complaints of right hip and inguinal C-shaped pain that had been ongoing for 3 months. Twelve years ago, the patient had undergone open anterior pelvic fixation (ilioinguinal incision) because of a simple type anterior wall fracture according to the Judet-Letournel classification (11). In the physical examination, the hip internal and external rotation movements were limited and painful, and the AP pelvis x-ray showed femoroacetabular screws (Figure 1). An incisional hernia due to the previous pelvic surgery was also determined (Figure 2). There are two treatment options for this case; open implant removal followed by open hernia repair, or open implant removal than laparoscopic hernia repair in a different session.

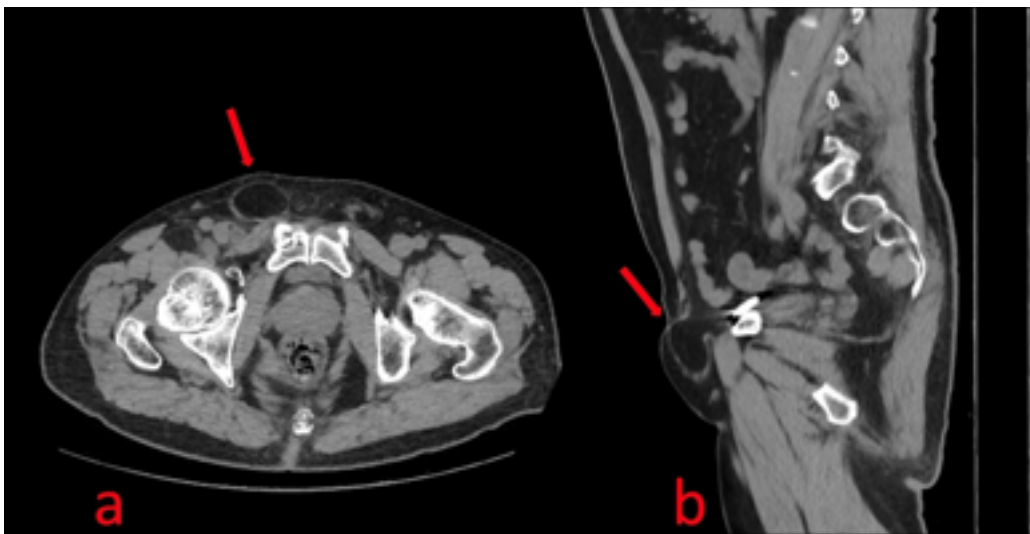
It was planned to perform Totally Extraperitoneal Herniorrhaphy (TEP), which is frequently used for inguinal hernias because of the similarity of the hernia localisation to the point of direct inguinal hernia. As the orthopaedic incision for removal of the screws is not compatible with the TEP technique (12), it was planned to first remove the implant laparoscopically, then to apply preperitoneal mesh.

### *Surgical Technique*

The surgery was performed with the patient positioned supine to provide appropriate fluoroscopy visualisation of the pelvic region. A bladder catheter was attached and it was ensured that the bladder was empty. With a 1cm incision inferior to the umbilicus, the subcutaneous adipose tissue was passed, then after passing through the Camper and Scarpa fascias, the musculus rectus abdominis fascia was reached. Passing carefully through the fascia, the preperitoneal area was reached. A 10 mm trochar with balloon was placed and inflated for perform dissection of peritoneum. The balloon was subsequently removed, and from this port, the preperitoneal area was insufflated with CO<sub>2</sub> to be at 12mmHg pressure. Preperitoneal exploration was performed with camera that had been advanced. The symphysis pubis was seen and the Retzius space was dissected. There was seen to be a hernia sac from a fascia defect, approximately 3cm in diameter, immediately right lateral of the symphysis



**Figure 1:** a) Preoperative pelvis anterior posterior (AP) X-ray shows the plate and free screws on the left ramus pubis and the screw that may extend into the femoroacetabular joint. b) Sagittal bone sequence computed tomography (CT) shows a screw in the joint and its location. c) Axial bone sequence CT shows the screws in the femoroacetabular joint.



**Figure 2:** CT Image of non-incarcerated incisional hernia sac due to previous surgery. No abdominal organ in sac because of spontaneous reduction by lay position during CT scan. a) Transvers view. b) Sagittal view.

pubis. Two 5mm laparoscopic ports were entered, each at 2cm below the existing port. Dissection was completed with sharp and blunt dissection as far as the Borgos space on the right lateral. The inguinal cord structures were seen. The hernia was medial of the cord structures and there was observed to be no relationship with these. The hernia sac was removed into to the abdomen after dissecting from surrounding tissue with sharp and blunt dissection. At this time the plate placed in the previous operation was detected and was defined as a guide. Dissection was continued based on the number of holes in the plate . Perioperative fluoroscopy was performed to

be able to determine the screws location (Figure 3). On visualisation of the proximity of the screws causing the problem, dissection was continued. The energy devices for cauterization were used at a minimal level to avoid injuries. On reaching the pin of the screws, a 5mm port was entered over this region to be a guide to the screwdriver, then the port was removed, and the screwdriver was entered via this route to the preperitoneal area, reaching the screws. The screws could not be excised with the magnetic screwdriver, the screws was removed by grasping the top of the screws with pincers. The scales remaining fixed were freed from surrounding tis-

sues with sharp and blunt dissection and were removed from the preperitoneal space. The camera was excised from a 10mm port and 15 x10cm mesh was advanced to the preperitoneal area. The mesh was spread on the anterior wall of the abdomen with one end reaching the symphysis and the other reaching the spina iliaca anterior superior (SIAS), and this was fixed with absorbable tuckers. After obtaining hemostasis, the ports were removed under laparoscopic view (Figure 4).

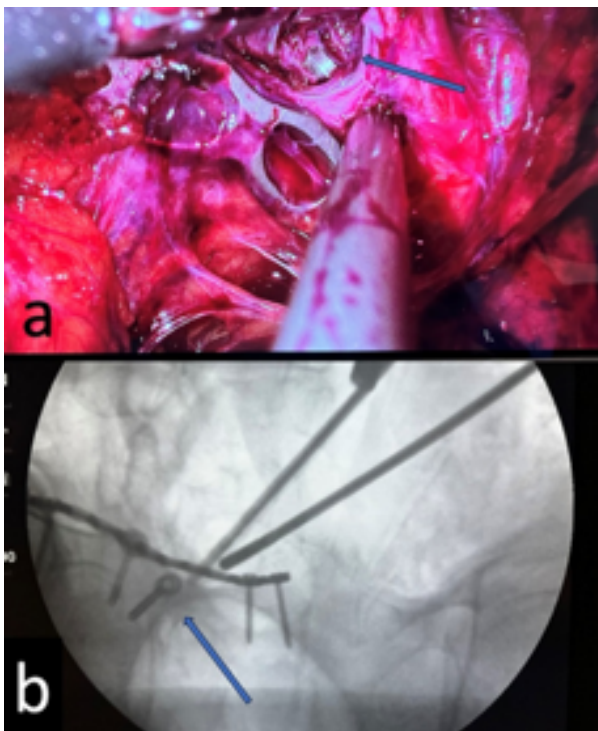
Postoperatively, the patient did not require blood transfusion, no wound site problems developed. At the 16th hour postoperatively, the patient was mobilised and no mechanical symptoms were identified. At the 40th hour the patient was discharged from hospital.

## DISCUSSION

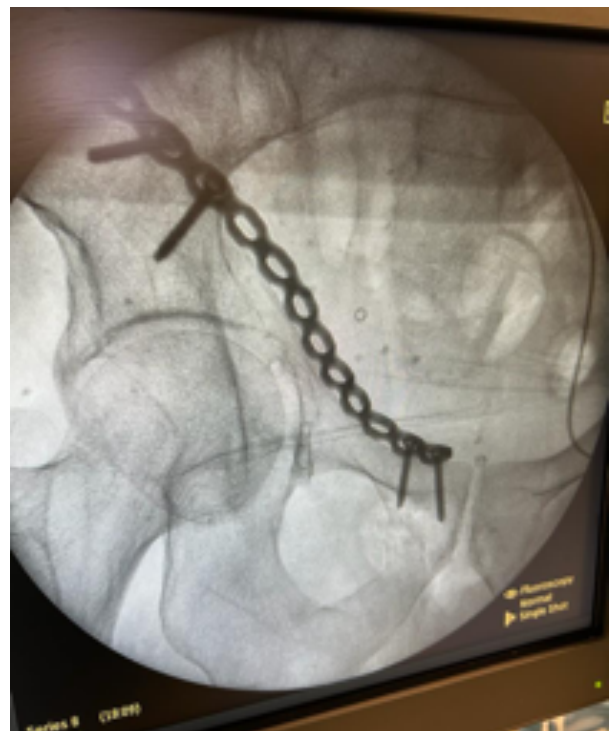This case is a technical note of a complication management after pelvic trauma surgery. Abdominal hernia treatment and intervention for pelvic ring can be performed laparoscopically in the same session. In the conventional surgical methods for pelvic fractures there are negative effects, such as bladder, vascular, nerve, and spermatic cord injuries, impaired hemodynamics

because of the formation of incisional hernia and diminished patient comfort postoperatively. These complications have directed many surgeons to percutaneous procedures, but endoscopic, arthroscopic, and laparoscopic treatments are still limited (7).

In this report, the case is presented of a patient who underwent open surgery 12 years ago, with intra-articular implant and incisional hernia. The patient presented with the complaint of the incisional hernia, and also imaging examination, screws which could be causing cartilage damage within the joint were determined. Francia et al. noted that the laparoscopic internal fixation technique, but there is only their own case report in literature. The most likely reason that there are no published studies of this technique in large patient series is the postoperative death of patients or that surgeons wish to keep the operating time short in cases of pelvic injuries which already have hemodynamic problems. Our patient returned to work after 1 week postoperatively, and currently at 3 months postoperatively has resumed an active life. Rather than complex cases that may require acute intervention for bleeding, laparoscopy can be considered for use in simple type fractures, conditions requiring re-operation such as implant removal, or for imaging purposes



**Figure 3:** a) Laparoscopic image of plate and screw localization.  
b) Fluoroscopy evaluation to determine localization during surgery.



**Figure 4.** Peroperative fluoroscopic imagination after screws removal.



such as in percutaneous fixations. However, there is a need for further studies of large series on this subject.

In most of digestive and urogenital system operations, laparoscopic methods are better than open methods in respect of complications (13,14). In the current case, the implant was removed and incisional hernia repair was performed laparoscopically. In current case same incision was used, a single operation day was given, and the length of stay in hospital and number of operations were reduced. If the screw had been removed separately before the hernia surgery, there would have been an incision in the hernia area and wound healing would have been expected. If the hernia surgery had been performed before the procedure to remove the implant, the mesh in the hernia area could have been damaged while removing the implant, and the operation could have been difficult. It can be considered that a surgeon with laparoscopy and orthopaedic experience can comfortably perform laparoscopic surgeries. The aim of publishing these technical notes is to demonstrate that laparoscopy can be used in pelvic surgery, and although the technical learning curve is more difficult compared to open surgery, better results can be obtained.

In conclusion, we presented that unique technique that never explained in literature before. We believe that this previously undescribed surgery will shed light on future combined surgeries and will also bring a different approach to implant excisions. However, studies with more cases are needed to better evaluate the results.

## REFERENCES

- Anglen JO. Pelvic Reduction Frame Facilitating Percutaneous Fixation to Pelvic Fractures. *Orthop Surg*. 2023;15: 1431-1433
- Sakamoto S, Doi K, Hattori Y, Supreeth S, Sonezaki S, Saeki Y. Arthroscopic Removal of a Missed Wooden Foreign Body in the Metacarpophalangeal Joint. *J Hand Microsurg*. 2021; 15: 227-229
- Lill H, Katthagen C, Voigt C. Technik und Stellenwert der arthroskopischen Implantatentfernung an der Schulter. *Orthopade*. 2011; 40: 79-84.
- Bhatia DN. Arthroscopic radial head implant removal and resection. *Arthrosc Tech*. 2016; 5: e705-e711.
- Grutter PW, McFarland EG, Zikria BA, Dai Z, Petersen SA. Techniques for suture anchor removal in shoulder surgery. *Am J Sports Med*. 2010; 38: 1706-10.
- Wong JM, Bewsher S, Yew J, Bucknill A, de Steiger R. Fluoroscopically assisted computer navigation enables accurate percutaneous screw placement for pelvic and acetabular fracture fixation. *Injury*. 2015; 46: 1064-8.
- Routt Jr MC, Simonian PT, Grujic L. Preliminary report: the retrograde medullary superior pubic ramus screw for the treatment of anterior pelvic ring disruptions: a new technique. *J Orthop Trauma*. 1995; 9: 35-44
- Chen H, Guan X, Wang X. Laparoscopic Abdominal Pelvic Anatomical Landmarks and Essentials of Surgical Exploration. In: *Natural Orifice Specimen Extraction Surgery: Gastrointestinal Tumor*. Springer, 2021 p: 33-40.
- Di Francia R, Tanner J-L, Marolleau J. The first use of laparoscopy to treat pelvic ring fractures: a case report. *Int J Surg Case Rep*. 2020; 76: 60-63.
- Thati VN, Kamat MM, Khandelwal NK. Laparoscopic extraction of fractured Kirschner wire from the pelvis. *J Minim Access Surg*. 2014; 10: 97-8.
- Alton TB, Gee AO. Classifications in brief: Letournel classification for acetabular fractures. *Clin Orthop Relat Res*. 2014; 472: 35-8.
- Zhou XL, Luo JH, Huang H, Wang YH, Zhang HB. Totally extraperitoneal herniorrhaphy (TEP): lessons learned from anatomical observations. *Minim Invasive Surg*. 2021; 21: 5524986
- Quah GS, Eslick GD, Cox MR. Laparoscopic appendectomy is superior to open surgery for complicated appendicitis. *Surg Endosc*. 2019; 33: 2072-2082.
- Nouralizadeh A, Tabatabaei S, Basiri A, Simforoosh N, Soleimani M, Javanmard B, et al. Comparison of open versus laparoscopic versus hand-assisted laparoscopic nephroureterectomy: a systematic review and meta-analysis. *J Laparoendosc Adv Surg Tech A*. 2018; 28: 656-681.

## Abbreviations list

TEP: Totally Extraperitoneal Herniorrhaphy  
AP: Anterior posterior  
CT: Computed tomography  
SIAS: Spina iliaca anterior superior

## Ethics approval and consent to participate

Written informed consent was obtained from the patient's legal guardian for the publication of this report. All procedures were conducted in accordance with the ethical standards of the Declaration of Helsinki.

## Availability of data and materials

Patient data are available to the corresponding author when requested with a reasonable justification.

## Competing interests

The authors declare no conflicts of interest with respect to the authorship and/or publication of this article.

## Funding

The authors received no financial support for the research and/or authorship of this article.

## Authors' contributions

All authors contributed to the study conception and design. The operation was performed by Cem Ilgin Erol and Bilal Karabak. Data collection and literature research were carried out by doctors Yavuz Şahbat and Cem Ilgin Erol. The authors carried out the final revision of the article together. All authors read and approved the final manuscript.

## Acknowledgements: None