

A Colorful Complication Of Urinary Tract Infection: Purple Urine Bag Syndrome

● Muhammed İslam ÖZER¹, ● Oğuzhan BOL¹, ● Ömer SALT¹, ● Necmi BAYKAN¹, ● Elif ÖZTEMÜR ÖZER², ● Felemez BÜDÜN¹

¹Kayseri City Hospital, Emergency Department, Kayseri, Türkiye

²Kayseri City Hospital, Radiology Department, Kayseri, Türkiye

Abstract

Purple urine bag syndrome is a rare and distinctive manifestation of urinary tract infection that has been observed in patients with urethral catheterisation. The underlying mechanism of this phenomenon involves a reaction between the bacterial enzymes present in infected urine and the polyvinyl chloride components of the urine bag, leading to the manifestation of a distinctive purple colouration. The condition predominantly afflicts elderly individuals, particularly those with prolonged urethral catheterisation, and is more prevalent in the female demographic. The present case study focuses on an elderly male patient residing in a nursing home, who has a history of Alzheimer's disease and chronic kidney disease who was brought to the emergency department with complaints of oral intake disorder and constipation.

Keywords: Purple urine bag syndrome, urinary tract infection, urethral catheterisation

Introduction

In certain instances, as a consequence of urinary tract infection, the urine bag may exhibit a purple hue subsequent to the interaction of bacterial enzymes present in the urine with the urine bag. This phenomenon is designated as purple urine bag syndrome. Tryptophan, an essential amino acid, is ingested alongside food and subsequently metabolised to indole by bacterial enzymes present in the intestine. Subsequently, indole is transported to the liver, where it undergoes a transformation into indoxyl sulfate through a process of hepatic conjugation. Indoxyl sulfate is excreted in the urine and is degraded to indoxyl under alkaline conditions by bacteria producing sulfatase and phosphatase. Oxidation of indoxyl releases indigo (blue) and indirubin (red) pigments. When these pigments come into contact with the urinary catheter and urine bag containing polyvinyl chloride, a purple discolouration of the urine is observed¹. Purple urine bag syndrome (PUBS) is usually seen in elderly patients who are followed with a long-term urinary catheter². The primary risk factor for this condition is the presence of a

long-term urinary catheter; other risk factors include female gender, constipation, recurrent urinary tract infections and dehydration^{3,4}. In case of constipation, the time that food spends in the intestine increases, making it easier for bacteria to multiply and for tryptophan to be metabolized into indole.

The objective of this case report is to remind physicians of the rare and alarming nature of purple urine bag syndrome, emphasising that it can only be diagnosed by inspection.

Case Report

An 80-year-old male patient was brought to the emergency department with complaints of oral intake disorder and constipation. It was learned that the patient was residing in a nursing home and was being monitored with a urethral catheter for a long time. A review of the patient's medical history revealed the following: the patient had Alzheimer's disease, chronic kidney disease and an operation for inguinal hernia six years prior. A physical examination of the patient revealed a moderate general condition, with blurred consciousness, poor orientation, dehydration, and cachexia.

Corresponding Author: Necmi BAYKAN **e-mail:** drnecmibaykan@gmail.com

Received: 31.01.2025 • **Revision:** 28.02.2025 • **Accepted:** 06.03.2025

Cite this article as: Ozer MI, Bol O, Salt O, Baykan N, Ozer EO, Büdün F. A Colorful Complication Of Urinary Tract Infection: Purple Urine Bag Syndrome Tox. 2025;1(1): 15-17

©Copyright 2018 by Emergency Physicians Association of Turkey - Available online at <https://dergipark.org.tr/ejtox>

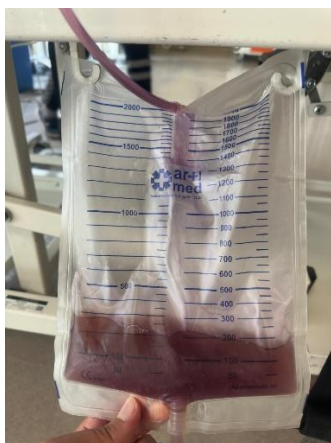


Figure 1: Urine bag containing purple colored urine at the patient's emergency room admission

The Glasgow Coma Scale (GCS) score was 14 points. On inspection, purple colored urine was in the urinary bag (Figure 1). The patient's vital signs upon admission to the emergency department were as follows: Blood pressure: 87/56 mmHg, pulse rate: 105/min, body temperature: 36 °C, oxygen saturation: 99%, fingertype blood sugar: 127 mg/dL, Electrocardiography: normal sinus rhythm. The patient's blood sample exhibited the following laboratory parameters: pH: 7.10, HCO_3^- : 10.4 mmol/L, WBC: 8890 $10^3/\mu\text{L}$, Hgb: 13.2 g/dL, Plt: 230.000 / μL , Creatine: 9.62 mg/dL, BUN: 169 mg/dL, GFR: 5 ml/dk/1.73m², Na: 152 mmol/L, Cl: 118 mmol/L, K: 5.2 mmol/L, CRP: 28.7 mg/L, PCT: 0.54 $\mu\text{g/L}$. The patient's urine test results are as follows: pH: 8.5, protein: +++++, nitrite: negative, leukocyte: +++. Urinary ultrasound (USG) was scheduled to determine the underlying cause of the elevated creatinine levels. The results of the ultrasound scan revealed a heterogeneous hypoechoic appearance of approximately 63*48 mm in size, occupying the bladder lumen, suggesting the presence of a bladder tumor. Emergency hemodialysis was planned, and a temporary central catheter was inserted. PUBS was not a factor contributing to the development of acute kidney injury, but acute kidney injury and PUBS were a condition that occurred simultaneously. The urethral catheter was changed. Following the collection of urine and blood cultures, as a result of the questioning, it was learned that the patient had no allergy and empirical intravenous antibiotics (ceftriaxone 1 gr) were started. The hemodialysis procedure was conducted in the emergency room, and the patient was subsequently transferred to the intensive care unit for continued observation and treatment. However, during the patient's follow-up in the intensive care unit, his clinical condition continued to deteriorate and he died due to his other underlying diseases.

Discussion

PUBS is an atypical presentation of a urinary tract infection (UTI) characterized by the presence of purple coloration in the urine. The purpose of presenting this case is to remind physicians of the existence of purple urine bag syndrome, a rare condition that can be alarming to the unaccustomed eye. The etiology of PUBS is multifactorial, including factors such as female gender, prolonged use of urethral catheters, the presence of alkaline urine (which can stimulate the release of indoxyl sulfatase by bacteria), constipation (which can lead to increased colonic bacterial proliferation), and chronic renal failure^{4,5}.

Urinary tract infections are more prevalent among women than men due to anatomical differences, including a shorter urethra and its proximity to the vagina and anus. Purple urine bag syndrome, a condition associated with catheter-associated urinary tract infection, it is understandable that the female gender is more common in reported cases. When compared to existing literature, the patient in our case was male, and this condition is observed less frequently in male patients.

The geriatric population is particularly susceptible to constipation, a condition that is associated with a number of factors, including neurological diseases, prolonged immobility, and age-related changes in bowel function. Nutritional habits also play a role in the development of constipation. Constipation has been demonstrated to result in an increase in bacteria in the intestinal flora, which can lead to secondary infections. Constipation is a common symptom reported in patients with purple urine bag syndrome. Our case also exhibited constipation, chronic renal disease, and alkaline urine, findings that align with existing literature on the subject.

The increased frequency and duration of urethral catheter use in geriatric patients residing in nursing homes and hospitals may be a contributing factor to the development of urinary tract infections^{6, 7}. Given the rising prevalence of catheter-associated urinary tract infections, a concomitant rise in reported cases of purple urine can be anticipated in forthcoming years.

Although purple urine bag syndrome is a clinical syndrome with a favorable prognosis, it is a clinical syndrome that should be considered due to the fact that the underlying causes and delayed treatment of urinary tract infections can be a significant cause of morbidity and mortality. In this particular case report, the patient succumbed to underlying diseases and exhibited an inadequate response to treatment, resulting in an exitus.

Conclusion

With this case report, purple urine bag syndrome, which can be diagnosed by inspection but is not encountered frequently, has been brought to the current literature data.

References

1. Popoola M, Hillier M. Purple urine bag syndrome as the primary presenting feature of a urinary tract infection. *Cureus*. 2022; 9: 14(4).
2. Su FH, Chung SY, Chen MH, Sheng ML, Chen CH, Chen YJ, et al. Case analysis of purple urine-bag syndrome at a long-term care service in a community hospital. *Chang Gung Med J*. 2005; 28(9): 636-42.
3. Pereira AP, Camarinha I, Ferreira A, Sevivas H, Reis M. Purple urine bag syndrome: a rare phenomenon managed in primary care. *Cureus*. 2024; 16(4): e57620.
4. Sabanis N, Paschou E, Papanikolaou P, Zagkotsis G. Purple urine bag syndrome: more than eyes can see. *Curr Urol*. 2019; 13(3): 125-32.
5. Peters P, Merlo J, Beech N, Giles C, Boon B, Parker B, et al. The purple urine bag syndrome: a visually striking side effect of a highly alkaline urinary tract infection. *Can Urol Assoc J*. 2011; 5(4): 233-4.
6. Cooper FP, Alexander CE, Sinha S, Omar MI. Policies for replacing long-term indwelling urinary catheters in adults. *Cochrane Database Syst Rev*. 2016; 7(7): CD011115.
7. Shen L, Fu T, Huang L, Sun H, Wang Y, Sun L, et al. 7295 elderly hospitalized patients with catheter-associated urinary tract infection: a case-control study. *BMC Infect Dis*. 2023; 23(1): 825.