

Research Article

Evaluation of ultrasonography and pathology results of incidental thyroid nodules detected on positron emission tomography-computed tomography: Single center results

Pozitron emisyon tomografi-bilgisayarlı tomografide insidental saptanan tiroid nodüllerinin ultrasonografi ve patoloji sonuçlarının değerlendirilmesi: Tek merkez sonuçları

✉ Gulce Ecem Kilic^{*1}, ✉ Cagatay Emir Onder¹, ✉ Koray Demirel², ✉ Muzaffer Caydere³,
✉ Meliha Korkmaz², ✉ Sevide Nur Firat¹

¹Department of Endocrinology and Metabolic Diseases, Ankara Training and Research Hospital, Ankara, Turkey

²Department of Nuclear Medicine, Ankara Training and Research Hospital, Ankara, Turkey

³Department of Pathology, Ankara Training and Research Hospital, Ankara, Turkey

Abstract

Aim: We aimed to determine the thyroid pathologies of patients with thyroid incidentalomas detected on 18F-FDG PET-CT, to obtain clinical, imaging, histopathology, and surgical treatment results, and to reveal the relationship between 18F-FDG uptake patterns and Maximum Standard Uptake Values (SUVmax) and diagnostic results.

Material and Methods: Data from 1837 patients who underwent PET-CT for any reason between January 2021 and February 2024 were retrospectively analyzed. Demographic data, ultrasonography (USG) and 18F-FDG PET-CT images, surgical and histopathological data of all patients meeting the inclusion criteria were reviewed.

Results: Patients with uptake (n = 71) were evaluated with US and thyroid nodules were detected in 46 patients (46/1837) (2.5%). Of the 22 nodules that were performed fine needle aspiration biopsy (FNAB), 12 were benign pathologies. Among the six nodules that underwent surgery (2 Bethesda V, 3 Bethesda VI, and 1 Bethesda III), three were diagnosed as benign, while the other three (13.6%) were confirmed as malignant pathology (papillary thyroid carcinoma). The malignancy rate in nodules with focal uptake was 16.6% (3/18). No statistically significant difference was observed in the median SUVmax values between benign and malignant nodules (p = 0.164).

Conclusion: It is necessary to determine the need for diagnostic examinations, to reveal the results of diagnostic interventions, and to increase awareness, especially in patients with focal thyroid uptake observed on 18F-FDG PET-CT imaging. When focal uptake is detected on 18F-FDG PET-CT, it is important to perform FNAB if it is considered a risky nodule in terms of US, regardless of the SUVmax value.

Keywords: positron emission tomography-computed tomography, thyroid nodule, ultrasonography

Corresponding Author*: Gulce Ecem Kilic, MD. Department of Endocrinology and Metabolic Diseases, Ankara Training and Research Hospital, Ankara, Turkey.

E-mail: gulcecan@hotmail.com

Orcid: 0000-0001-9511-4593

Doi: 10.18663/tjcl.1641091

Received: 17.02.2025 accepted: 05.05.2025

Öz

Amaç: ¹⁸F-FDG PET-BT’de tiroid insidentolomasi saptanan hastaların tiroid patolojilerini saptamayı, klinik, görüntüleme, histopatoloji ve cerrahi tedavi sonuçlarını elde etmeyi, ¹⁸F-FDG tutulum paternleri ve Maksimum Standart Uptake Değerleri(SUVmax) ile tanısal sonuçlar arasındaki ilişkiyi ortaya koymayı amaçladık.

Gereç ve Yöntemler: Ocak 2021 ile Şubat 2024 arasında herhangi bir nedenle PET-BT çekilen 1837 hastanın verileri retrospektif olarak analiz edildi. Dahil etme kriterlerini karşılayan tüm hastaların demografik verileri, ultrasonografi(USG) ve ¹⁸F-FDG PET-BT görüntüleri, cerrahi ve histopatolojik verileri incelendi.

Bulgular: Tutulum gösteren hastalar(n = 71) USG ile değerlendirilmiş, 46 hastada (%2,5) tiroid nodülü saptanmıştı . İnce iğne aspirasyon biyopsisi (İİAB) yapılan 22 nodülden 12’si benign olarak raporlanmıştı. Cerrahiye verilen 6 nodülün (2’si Bethesda V, 3’ü Bethesda VI ve 1’i Bethesda III) 3’ü benign, diğer 3’ü (%13,6) ise malign (papiller tiroid karsinomu) olarak sonuçlanmıştı. Fokal tutulum gösteren nodüllerdeki malignite oranı %16,6 (3/18) idi. Benign ve malign nodüllerin ortalama SUVmax değerleri arasında ise istatistiksel fark saptanmamıştı (p=0,164).

Sonuç: Özellikle ¹⁸F-FDG PET-BT görüntülemesinde fokal tiroid tutulumu gözlenen hastalarda tanısal incelemelere olan ihtiyacın belirlenmesi, sonuçlarının ortaya konulması ve farkındalığın artırılması için SUVmax değerinden bağımsız olarak ultrasonografik açıdan riskli nodüllere İİAB yapılması önemlidir.

Anahtar Kelimeler: pozitron emisyon tomografi-bilgisayarlı tomografi, tiroid nodülü, ultrasonografi

Introduction

Thyroid incidentaloma is often defined as an asymptomatic thyroid lesion detected incidentally during imaging studies performed for other reasons and whose frequency increases with age. The prevalence of thyroid nodules detected by imaging methods was 23.5% in the young population, while it was found to be 37% in those over the age of 65 [1]. Malignancy is detected in 5% of thyroid nodules. The incidence of thyroid cancer in Turkey in 2022 was reported as 6.4% [2].

Fluorine-18 fluorodeoxyglucose positron emission tomography-computed tomography (¹⁸F-FDG PET-CT) is an increasingly utilized functional imaging technique for the diagnosis, staging, and follow-up of oncological, cardiac, and neurological diseases. Therefore, increased diffuse or focal ¹⁸F-FDG uptake in the thyroid gland is frequently encountered in daily clinical routine ¹⁸F-FDG PET-CT. While these uptakes may be physiological, they can also be observed in toxic nodular goiter, multinodular goiter, thyroiditis, and thyroid malignancies. Incidental focal increased uptake in the thyroid gland detected on ¹⁸F-FDG PET-CT is observed in approximately 2-3%, and histopathological data indicate a malignancy risk of 35-40% in a significant portion of these cases [3-5]. The likelihood of malignancy increases in thyroid lesions demonstrating uptake on ¹⁸F-FDG PET-CT, whereas nodules without uptake are generally considered benign. Due

to its high sensitivity and specificity, it can exclude malignancy in indeterminate thyroid nodules, particularly those larger than 15 mm, with a sensitivity of approximately 95-100% without requiring additional testing [6].

Evidence-based data have shown that thyroid incidentalomas are not rare, and the risk of malignancy, especially if the focal pattern is evident on ¹⁸F-FDG PET-CT, cannot be ignored, thus requiring further clinical and interventional evaluation [5]. Therefore, in this study, we aimed to determine the thyroid pathologies of patients with thyroid incidentalomas detected on ¹⁸F-FDG PET-CT, to obtain clinical, imaging, histopathology, and surgical treatment results, and to reveal the relationship between ¹⁸F-FDG uptake patterns and Maximum Standard Uptake Values (SUVmax) and diagnostic results.

Material and Methods

This study was conducted retrospectively by scanning hospital data records from the Endocrinology and Metabolism Diseases Clinic of our hospital between January 2021 and February 2024. A total of 1837 adult patients over the age of 18 who showed uptake in the thyroid gland on ¹⁸F-FDG PET-CT were included in the study. Patients with a previously diagnosed thyroid cancer, those with a "Maximum Standardized Uptake Value" (SUVmax) within normal physiological limits on ¹⁸F-FDG PET-CT, patients with repeat imaging, and those with incomplete medical data (ultrasonography, biopsy, pathology, etc.) were

excluded from the study. After the retrospective screening, demographic data, ultrasonography images, 18F-FDG PET-CT images, surgical, and histopathological data of all patients meeting the inclusion criteria were examined.

Ultrasonography (US) of the patients was performed by experienced endocrinologists with at least 5 years of experience, using a Hitachi HI VISION Preirus device (Hitachi Medical Systems, Tokyo, Japan) with a linear transducer probe of central frequency 7.5-15 MHz. Thyroid nodules were classified according to the European Thyroid Imaging Reporting and Data System (EU-TIRADS-2017), and the necessity of fine-needle aspiration biopsy (FNAB) was determined [7]. FNAB was performed using a 22 Gauge needle with an aspiration technique under US guidance, collecting samples from at least two different areas of the nodule. The samples were spread on glass slides, air-dried, and immediately sent to pathology. Giemsa-stained samples examined in the pathology department between 2021 and 2024 were retrospectively re-evaluated and reported according to the Bethesda 2023 Thyroid Cytology Reporting System [8].

18F-FDG PET/CT imaging was performed 60 minutes after FDG injection using a PET-CT scanner (Biograph 6; Siemens Medical Systems, Erlangen, Germany). FDG injection was performed after the patients had fasted for 6 hours and fasting blood glucose levels were below 150 mg/dl. 18F-FDG was administered intravenous at a dose of approximately 5.18 MBq/kg (0.14 mCi/kg). Immediately after the acquired CT scan for localization and attenuation correction, the PET scan was acquired in 5-7 bed positions with an imaging time of 4 minutes for each. 18F-FDG PET/CT images were reviewed by two experienced nuclear medicine physicians and visual and semiquantitative analysis of uptake in the thyroid gland was performed. Whereas focal 18F-FDG uptake was defined as a localized uptake covering less than an entire thyroid lobe, uptake covering at least one entire thyroid lobe was analyzed under the diffuse uptake category in this study. Due to the retrospective design of the study, interobserver agreement was not assessed. We also acknowledge that interobserver variability may influence the results. The study was approved by the ethics committee of the Ankara Training and Research Hospital (approval date and number: 17 April 2024-E-24/60). The study was performed in accordance with the Declaration of Helsinki.

Statistical Analysis

Data were analyzed using the SPSS 27 (Statistical Package for Social Sciences, Chicago, IL, USA). The normality of

distribution was assessed using the Kolmogorov-Smirnov test. Normally distributed data were presented as mean \pm standard deviation (SD) and n (%), while non-normally distributed data were expressed as median (minimum-maximum). The Mann-Whitney U test was used to compare non-parametric independent variables. The relationship between numerical variables was evaluated using the Spearman correlation test for non-normally distributed data. In this study, the statistical significance level was accepted as $p < 0.05$.

Results

Among 1837 patients who underwent 18F-FDG PET-CT imaging due to known or suspected cancer (excluding thyroid cancer), FDG uptake was detected in 124 patients. While 53 patients were excluded from the study, incidental thyroid uptake was found in 71 patients (3.8%) (Figure 1). Of these, 43 patients (2.3%) had focal uptake, while 28 patients (1.5%) had diffuse thyroid uptake. The mean age of the patients was 59.25 \pm 13.17 years, with the majority being female (74.6%).

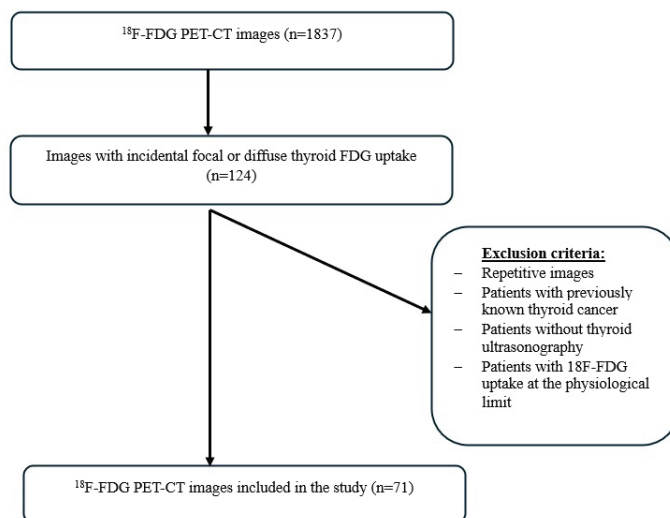


Figure 1. Flow diagram of the search strategy for focal or diffuse thyroid uptake on 18F-FDG PET-CT

Patients with uptake (n = 71) were evaluated with US and thyroid nodules were detected in 46 patients (46/1837) (2.5%) (Figure 2). The median nodule size was 1.5 cm (0.4-5.8 cm), with focal uptake present in 36 patients (78.3%) and diffuse uptake in 10 patients (21.7%). FNAB was performed in 18 of the focal uptake cases and 4 of the diffuse uptake cases. It was determined that the US findings of 25 patients without detected nodules were consistent with chronic thyroiditis, and the majority of these patients (72%) exhibited diffuse uptake on 18F-FDG PET-CT imaging.

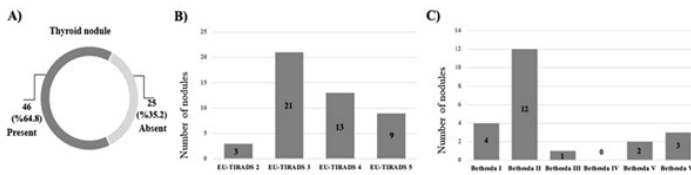


Figure 2. Evaluation of patients with focal or diffuse thyroid uptake on 18F-FDG PET-CT for the presence of nodules and nodule characteristics by Thyroid US, A) Presence of nodules on US, B) Distribution of nodules on US according to EU-TIRADS classification, C) Distribution of fine needle aspiration cytology result of nodules according to Bethesda categorization.

The indications for performing 18F-FDG PET-CT in 46 patients with thyroid nodules detected in US are listed in Table 1.

Table 1. Indications for 18F-FDG PET-CT in patients with nodules detected in ultrasonography.

| Indications | N |
|-------------------------------|----|
| Breast cancer | 14 |
| Colon cancer | 7 |
| Solitary pulmonary nodule | 5 |
| Gastric cancer | 3 |
| Lung cancer | 3 |
| Malignancy of unknown primary | 3 |
| Endometrial cancer | 3 |
| Squamous cell carcinoma | 2 |
| Non-Hodgkin lymphoma | 2 |
| Angiosarcoma | 1 |
| Laryngeal cancer | 1 |
| Other causes | 3 |

Among the 46 nodules, 24 were considered benign or low-risk for malignancy according to the EU-TIRADS classification, with no further investigation recommended, and therefore, a biopsy was not performed (Figure 2) [7]. The remaining 22 patients had nodules with sonographic features requiring further evaluation, leading to fine-needle aspiration biopsy (FNAB). Among the 22 biopsied nodules, 12 were reported as benign (Bethesda II), two as suspicious for malignancy (Bethesda V), three as malignant (Bethesda VI), and one as atypia of undetermined significance

(Bethesda III). Four biopsy results were reported as non-diagnostic (Bethesda I) (Figure 2) [8].

No surgical resection was performed on the 12 cytologically benign nodules. The four nodules were cytologically non-diagnostic (Bethesda I) and these patients refused surgical resection by their own decision. Among the six nodules that underwent surgery (2 Bethesda V, 3 Bethesda VI, and 1 Bethesda III), three were diagnosed as benign, while the other three (13.6%) were confirmed as malignant pathology (papillary thyroid carcinoma) [8]. All malignant nodules exhibited focal uptake on 18F-FDG PET-CT. The malignancy rate in nodules with focal uptake was 16.6% (3/18).

The median SUVmax value of the 71 incidental thyroid gland lesions (with either diffuse or focal uptake) was 4.59 (range: 2.3-17.6). There was no significant difference in SUVmax values between diffuse and focal uptake groups (diffuse uptake: 5.07 [2.3-12] vs. focal uptake: 4.4 [2.3-17.6], $p = 0.326$). The median SUVmax value of the 46 US-confirmed thyroid nodules was 4.45 (2.3-17.6), whereas the median SUVmax value of patients without detected nodules ($n = 25$) was 4.78 (2.3-12) ($p = 0.459$). Among patients with focal uptake and detected nodules, there was no significant difference in SUVmax values between those who underwent FNAB and those who did not (5.84 vs. 5.74, $p = 0.501$). The median SUVmax value of the 15 confirmed benign lesions was calculated as 4.59 (2.7-13.3), while the detailed characteristics of the three malignant nodules are presented in Table 2. No statistically significant difference was observed in the median SUVmax values between benign and malignant nodules ($p = 0.164$).

Finally, no correlation was found between SUVmax values and nodule size, Bethesda classification, or EU-TIRADS categorization (Table 3). However, a positive correlation was observed between the Bethesda classification and both nodule size and EU-TIRADS categorization ($r = 0.385$, $p = 0.008$ and $r = 0.550$, $p < 0.001$, respectively).

Table 2. Characteristics of thyroid nodules with proven malignancy.

| Case | Size (cm) | SUVmax* | Pattern of uptake on PET/ CT | EU-TIRADS | Bethesda | Post-surgical diagnosis |
|------|-----------|---------|------------------------------|-----------|----------|-------------------------|
| 1 | 3.2 | 5.7 | Focal | 5 | VI | Papillary thyroid ca |
| 2 | 1.4 | 5.5 | Focal | 5 | VI | Papillary thyroid ca |
| 3 | 5.8 | 14.4 | Focal | 5 | V | Papillary thyroid ca |

*Maximum Standard Uptake Values

Table 3. Evaluation of correlation analysis between SUVmax values and nodule size, Bethesda classification and EU-TIRADS.

| | SUVmax | Nodule size | Bethesda | EU-TIRADS |
|-------------|--------------------|---------------------|---------------------|---------------------|
| SUVmax | N/A | r=0.048 p=0.750 | r=0.139 p=0.359 | r=0.188 p=0.210 |
| Nodule size | r=0.048 p=0.750 | N/A | r=0.385 p=0.008* | r=0.268 p=0.072 |
| Bethesda | r=0.139 p=0.359 | r=0.385 p=0.008* | N/A | r=0.550 p<0.001* |
| EU-TIRADS | r=0.188 p=0.210 | r=0.268 p=0.072 | r=0.550 p<0.001* | N/A |

The relationship between numerical variables was evaluated with the Spearman correlation test for data that did not show normal distribution. $p<0.05$ was considered statistically significant. N/A: not applicable

Discussion

Nowadays, the prevalence of incidental thyroid nodules is increasing with the increasing frequency of diagnostic imaging. Different rates for the prevalence of incidental thyroid nodules detected by 18F-FDG PET-CT have been reported in the literature. In a meta-analysis, the prevalence in the included studies ranged between 0.16% and 11.74%, while the pooled prevalence was reported as 2.22% [9]. In our research, incidental thyroid gland uptake was found to be 3.8% and thyroid nodule prevalence was 2.5%.

As is known, uptake patterns in the thyroid gland and SUVmax values in 18F-FDG PET-CT are important in the diagnosis and follow-up of thyroid diseases. Focal thyroid uptake is highly suspicious for malignancy [9]. In the literature, focal thyroid uptake has been reported to be around 2% [3]. Similarly, this rate was found to be 2.3% in our study and focal uptake was seen in all malignant nodules. Another important point is that the SUVmax value is directly proportional to the malignancy of the thyroid nodule [4]. Different cut-off values have been reported in the literature to interpret the benign or malignant status of a thyroid nodule detected by 18F-FDG PET-CT according to the SUVmax value. For example, Kang et al. reported the cut-off value for SUVmax as 4.2 [10], while Bae et al reported the cut-off value for SUVmax as 3.5 [11]. On the contrary, Kim et al, Are et al, and Bogsrud et al reported no difference in SUVmax between benign and malignant lesions [12-14]. In our study, while the median SUVmax value of 15 benign lesions was 4.59, the median SUVmax value of 3 malignant lesions was 5.7 and no statistical difference was found between the median SUVmax values of benign and malignant nodules ($p = 0.164$). The fact that there were 3 malignant nodules prevented us from making a healthy statistic to determine the cut-off. However, numerically, all of the

SUVmax values of the malignant nodules were above the cut-off values specified in the literature ($SUVmax > 5.5$). This may be due to the fact that the number of nodules biopsied in this study was small, and two of the malignant thyroid nodules were measured with lower SUVmax due to partial volume effects because of their small size [15]. We also explicitly note that limited sample size may have reduced the power to detect a statistically significant difference. Therefore, when focal uptake is seen on 18F-FDG PET-CT, we recommend FNAB if it is considered a risky nodule in terms of US, regardless of the SUVmax value.

When focal thyroid uptake is detected incidentally on 18F-FDG PET-CT, the thyroid should be evaluated with US. Biopsy is recommended for >1 cm EU-TIRADS-4/5 nodules and >2 cm EU-TIRADS-3 nodules. For <2 cm EU-TIRADS-2/3 nodules, follow-up with US at 6-12 month intervals is recommended [16]. Biopsy is not recommended for EU-TIRADS-2 nodules since no malignancy was detected in any of the studies [17]. EU-TIRADS-3/4/5 nodules <1 cm may be considered for biopsy only if there is a high risk and aggressive US features [18]. Diffuse FDG uptake in the thyroid gland may be physiological. However, it may also be seen in cases of increased gland activity or inflammation (Hashimoto's thyroiditis, Graves' disease, subacute thyroiditis, post-RAI treatment thyroiditis, etc.). For example, diffuse FDG uptake caused by chronic thyroiditis may hide the focal nodule at the base. Although the probability of malignancy is low in diffuse FDG uptake, this condition cannot be excluded [12]. Therefore, when necessary, an evaluation with ultrasound can guide decision-making. In our study, we decided to perform FNAB on four thyroid incidentalomas showing diffuse uptake after evaluating with the US. According to the American Thyroid Association (ATA) guideline, if there is diffuse FDG uptake in chronic lymphocytic thyroiditis proven by US and laboratory findings, further investigation is not required

[19]. The British Thyroid Association (BTA) guidelines state that thyroid nodules with focal uptake on 18F-FDG PET-CT are high-risk nodules and recommend US and TIAB [20]. To optimize clinical applicability, we use a follow-up strategy based on ultrasound risk stratification using the EU-TIRADS system. In our study, based on EU-TIRADS criteria, 24 of 46 nodules were not subjected to FNAB because they had benign and low-risk characteristics. Since the design of our study was retrospective, further investigation into the outcomes and follow-up of benign nodules could not be performed. According to some opinions, it has been reported that incidental thyroid nodules that are found to be malignant are overemphasized and further investigated despite the low mortality rate and mild prognosis [21]. In a consensus supporting this view, it was stated that further investigation may not be performed if the patient's 5-year life expectancy is low because the probability of the nodule being malignant is less than 15% [18].

In the literature, the malignancy rates of thyroid nodules showing FDG uptake have been reported at different rates. For example, in a meta-analysis including 22 studies, it was reported that the malignancy rate of thyroid nodules showing FDG thump was 35% [3]. In another meta-analysis, the malignancy rate was reported as 30.8% [9]. On the contrary, in other studies in the literature in which most of the thyroid nodules showing FDG uptake were followed up, this rate was reported to be around 15% and it was actually shown that the malignancy rate may be lower [22]. In our study, the malignancy rate in all nodules showing uptake (focal and diffuse) was found to be 13.6% (3/22), while the malignancy rate in nodules showing focal uptake was found to be 16.6% (3/18). Similarly, in the study of Elzein et al., 16 of 30 nodules in 1730 FDG PET/CT scans underwent FNAB and malignancy was detected in only 2 (12.5%) [23]. The relatively low malignancy rates in our study compared to the literature may be related to the risk classification we used to evaluate the nodules. In addition, the fact that not only histopathology but also cytopathology reports were used in some of the other studies in the literature to assess the risk of malignancy may have contributed to the higher detection of malignancy rates [12].

The pathology of the 3 malignant nodules in our study was reported as papillary thyroid carcinoma, the most common type of differentiated thyroid cancer in the literature [3]. Metastasis was not detected in any of the cases.

An association between thyroid nodules and breast cancer is known [24]. A recent study by Chen-Yu Ma et al. showed an

increased frequency of thyroid nodules in patients with breast cancer (especially in hormone-positive breast cancer patients) [25]. In this study, breast cancer was found to be the most common malignancy accompanying thyroid nodules.

The first limitation of our study is the small number of patients, as the PET-CT device in our hospital has been in use since 2021. Secondly, only the EU-TIRADS classification was used as the US risk classification when evaluating nodules. Thirdly, since it was a retrospective study, some data cannot be accessed. On the other hand, the strength of our study is that the malignancy risk of the nodules was confirmed by histopathology.

In conclusion, this current study demonstrated that when focal uptake is observed on 18F-FDG PET-CT, FNAB should be performed if the nodule is considered ultrasonographically suspicious, regardless of the SUVmax value. During the diagnosis or follow-up of oncologic patients, thyroid uptake in PET-CT may be overlooked due to a focus on the primary malignancy, and therefore, these patients may not be referred to endocrinology clinics. To avoid missing such cases, it is essential to determine the need for diagnostic evaluation in patients with focal thyroid uptake in 18F-FDG PET-CT, to clarify outcomes through diagnostic interventions, and to increase awareness. Establishing optimal management will not only reduce unnecessary FNABs and subsequent surgeries but also allow for a personalized approach based on the primary malignancy, performance status, and survival of oncologic patients. Therefore, further guiding studies and clinical guidelines are needed for the diagnosis, management, and follow-up of incidental thyroid nodules showing uptake in PET-CT.

Declaration of conflicting interests

The authors declared no conflicts of interest with respect to the authorship and/or publication of this article.

Funding

The authors received no financial support for the research and/or authorship of this article.

Ethics Approval

The study was approved by the ethics committee of the Ankara Training and Research Hospital (approval date and number: 17 April 2024-E-24/60).

Author Contributions

All of the authors declare that they have all participated in the design, execution, and analysis of the paper, and that they have approved the final version.

References

1. Erdoğan M, Atlı T, Ekinci C, Genç Y, Gökmen H, Erdoğan G. Spectrum and prevalence of thyroid disorders in the elderly living in an iodine deficient community. *Turk Jo Geriatr* 2002; 5:4 9-53.
2. Bray F, Laversanne M, Sung H, Ferlay J, Siegel RL, Soerjomataram I et al. Global cancer statistics 2022: GLOBOCAN estimates of incidence and mortality worldwide for 36 cancers in 185 countries. *CA Cancer J Clin* 2024; 74: 229-63.
3. Treglia G, Bertagna F, Sadeghi R, Verburg FA, Ceriani L, Giovanella L. Focal thyroid incidental uptake detected by (1) (8)F-fluorodeoxyglucose positron emission tomography. Meta-analysis on prevalence and malignancy risk. *Nuklearmedizin* 2013; 52: 130-6.
4. Bertagna F, Treglia G, Piccardo A, Giubbini R. Diagnostic and clinical significance of F-18-FDG-PET/CT thyroid incidentalomas. *J Clin Endocrinol Metab* 2012; 97: 3866-75.
5. Signore G, Albano D, Giovanella L, Bertagna F, Treglia G. Evidence-based data about prevalence and risk of malignancy of thyroid incidentalomas detected by different PET radiopharmaceuticals. *Cur Radiopharmaceutical* 2020; 13: 89-93.
6. Vriens D, de Wilt JH, van der Wilt GJ, Netea-Maier RT, Oyen WJ, de Geus-Oei LF. The role of [18F]-2-fluoro-2-deoxy-d-glucose-positron emission tomography in thyroid nodules with indeterminate fine-needle aspiration biopsy: systematic review and meta-analysis of the literature. *Cancer* 2011; 117: 4582-94.
7. Russ G, Bonnema SJ, Erdogan MF, Durante C, Ngu R, Leenhardt L. European Thyroid Association Guidelines for Ultrasound Malignancy Risk Stratification of Thyroid Nodules in Adults: The EU-TIRADS. *Eur Thyroid J* 2017; 6: 225-37.
8. Ali SZ, Baloch ZW, Cochand-Priollet B, Schmitt FC, Vielh P, VanderLaan PA. The 2023 Bethesda System for reporting thyroid cytopathology. *J Am Soc Cytopathol* 2023; 12: 319-25.
9. de Leijer JF, Metman MJH, van der Hoorn A, Brouwers AH, Kruijff S, van Hemel BM, et al. Focal Thyroid Incidentalomas on (18)F-FDG PET/CT: A Systematic Review and Meta-Analysis on Prevalence, Risk of Malignancy and Inconclusive Fine Needle Aspiration. *Front Endocrinol (Lausanne)* 2021; 12: 723394.
10. Kang KW, Kim SK, Kang HS, Lee ES, Sim JS, Lee IG et al. Prevalence and risk of cancer of focal thyroid incidentaloma identified by 18F-fluorodeoxyglucose positron emission tomography for metastasis evaluation and cancer screening in healthy subjects. *J Clin Endocrinol Metab* 2003; 88: 4100-4.
11. Bae JS, Chae BJ, Park WC, Kim JS, Kim SH, Jung SS et al. Incidental thyroid lesions detected by FDG-PET/CT: prevalence and risk of thyroid cancer. *World J Surg Oncol* 2009; 7: 63.
12. Kim TY, Kim WB, Ryu JS, Gong G, Hong SJ, Shong YK. 18F-fluorodeoxyglucose uptake in thyroid from positron emission tomogram (PET) for evaluation in cancer patients: high prevalence of malignancy in thyroid PET incidentaloma. *Laryngoscope* 2005; 115: 1074-8.
13. Are C, Hsu JF, Schoder H, Shah JP, Larson SM, Shaha AR. FDG-PET detected thyroid incidentalomas: need for further investigation? *Ann Surg Oncol* 2007; 14: 239-47.
14. Bogsrud TV, Karantanis D, Nathan MA, Mullan BP, Wiseman GA, Collins DA et al. The value of quantifying 18F-FDG uptake in thyroid nodules found incidentally on whole-body PET-CT. *Nucl Med Commun* 2007; 28: 373-81.
15. Kresnik E, Gallowitsch HJ, Mikosch P, Stettner H, Igerc I, Gomez I et al. Fluorine-18-fluorodeoxyglucose positron emission tomography in the preoperative assessment of thyroid nodules in an endemic goiter area. *Surgery* 2003; 133: 294-9.
16. Do Cao C, Haissaguerre M, Lussey-Lepoutre C, Donatini G, Raverot V, Russ G. SFE-AFCE-SFMN 2022 Consensus on the management of thyroid nodules: Initial work-up for thyroid nodules. *Ann Endocrinol (Paris)* 2022; 83: 380-8.
17. Trimboli P, Paone G, Treglia G, Virili C, Ruberto T, Ceriani L et al. Fine-needle aspiration in all thyroid incidentalomas at (18) F-FDG PET/CT: Can EU-TIRADS revise the dogma? *Clin Endocrinol (Oxf)* 2018; 89: 642-8.
18. Wadsley J, Balasubramanian SP, Madani G, Munday J, Roques T, Rowe CW et al. Consensus statement on the management of incidentally discovered FDG avid thyroid nodules in patients being investigated for other cancers. *Clinical Endocrinology* 2024; 101: 557-61.

19. Haugen BR, Alexander EK, Bible KC, Doherty GM, Mandel SJ, Nikiforov YE et al. 2015 American Thyroid Association Management Guidelines for Adult Patients with Thyroid Nodules and Differentiated Thyroid Cancer: The American Thyroid Association Guidelines Task Force on Thyroid Nodules and Differentiated Thyroid Cancer. *Thyroid* 2016; 26: 1-133.
20. Perros P, Boelaert K, Colley S, Evans C, Evans RM, Gerrard Ba G et al. Guidelines for the management of thyroid cancer. *Clin Endocrinol (Oxf)* 2014;81 Suppl 1: 1-122.
21. McCrory D, Li C, Devlin B. Five-year review of incidental thyroid nodule management in the ENT outpatient department. *Ann Thyroid* 2023; 8: 12.
22. Thuillier P, Roudaut N, Crouzeix G, Cavarec M, Robin P, Abgral R et al. Malignancy rate of focal thyroid incidentaloma detected by FDG PET-CT: results of a prospective cohort study. *Endocr Connect* 2017; 6: 413-21.
23. Elzein S, Ahmed A, Lorenz E, Balasubramanian SP. Thyroid incidentalomas on PET imaging--evaluation of management and clinical outcomes. *Surgeon* 2015; 13: 116-20.
24. Li H, Wang Z, Liu JS, Zou BS, Chen HR, Xu Z et al. Association Between Breast and Thyroid Lesions: A Cross-Sectional Study Based on Ultrasonography Screening in China. *Thyroid* 2020; 30: 1150-8.
25. Ma CY, Liang XY, Ran L, Hu L, Zeng FL, She RL et al. Prevalence and risk factors of thyroid nodules in breast cancer women with different clinicopathological characteristics: a cross-sectional study. *Clin Transl Oncol* 2024; 26: 2380-7.

This article is an open access article distributed under the terms and conditions of the Creative Commons Attribution (CC BY) license (<http://creativecommons.org/licenses/by/4.0/>).